wjpmr, 2017,3(9), 304-306

SJIF Impact Factor: 4.103

WORLD JOURNAL OF PHARMACEUTICAL AND MEDICAL RESEARCH

www.wjpmr.com

Case Report

ISSN 2455-3301

WJPMR

LINEAR PSORIASIS – A NOT UNCOMMON MANIFESTATION

Dr. Padam Kumar M.[1] and Dr. Jayakar Thomas*[2]

[1]Junior Resident, Department of Dermatology, Sree Balaji Medical College, and Hospital, Chrompet, Chennai. India.
[2]Professor & Head, Department of Dermatology, Sree Balaji Medical College, and Hospital, Chrompet, Chennai. India.

***Corresponding Author: Dr. Jayakar Thomas**

Professor & Head, Department of Dermatology, Sree Balaji Medical College, and Hospital, Chrompet, Chennai. India.

Article Received on 05/07/2017 **Article Revised on 25/08/2017** **Article Accepted on 15/08/2017**

ABSTRACT

Psoriasis is a chronic immunologically mediated papulosquamous disorder with various patterns of presentations and systemic manifestations. Linear psoriasis is a rare variant of psoriasis, commonly occurring over the limbs along the lines of Blaschko. Here in we report 4 cases of psoriasis along the Blaschko's lines who responded well to the standard anti-psoriatic treatment.

KEYWORDS: Linear psoriasis, Blaschko's line, superimposed linear psoriasis.

INTRODUCTION

Psoriasis is a chronic immunologically mediated papulo-squamous disorder with various patterns of presentations and systemic manifestations. Linear psoriasis also known as zonal psoriasis or naevoid psoriasis is a rare variant of psoriasis. It commonly occurs along the lines defined by Alfred Blaschko. It represents a form of cutaneous genetic mosaicism.[1] Occasional occurrence as a Koebner's response following herpes zoster is also reported as linear psoriasis and more aptly psoriasis zosteriformis. [2] Here in we report 4 cases of psoriasis along the lines of Blaschko's which were confirmed by skin biopsy. All the cases responded well to the standard anti-psoriatic treatment.

CASE REPORT

Case 1

A 19 year old male presented with red scaly lesions since 5 years of age over dorsum of right hand extending up to the extensor of right forearm, arm and upper back. On closer examination, multiple erythematous plaques covered with silvery white scales were seen in a linear pattern along the lines of Blaschko's. [Figure 1.A] Auspitz's sign was positive. PASI score was 8.1. Differentials considered were linear psoriasis and linear lichen planus. Patient was subjected to 4mm punch biopsy. Histopathology revealed hyperkeratosis, parakeratosis, absent granular layer with regular acanthosis. Dilated and tortuous blood vessels were seen in the papillary dermis. Neutrophil rich, Munro's micro abscesses were noted in the corneal layer. [Figure 1.C & 1.D] Sparse dermal infiltrate was noted. Patient was started with topical emollient in day and topical mid-potent corticosteroid in the night. Post work up for methotrexate, with no contraindication, patient was started on 7.5 mg weekly dose of MTX. 6 weeks post treatment the lesions resolved rapidly to a PASI score of 3.0. [Figure 1.B].

Case 2

A 6 years old girl presented with multiple silvery white scaly skin lesions over her right upper limb, left side of her abdomen, left thigh and left leg in a linear pattern along multiple Blaschko's lines. [Figure 2.A] Few isolated plaques were noted over the shoulders and on the chest. Auspitz's sign was positive. A diagnosis of linear psoriasis was made which was confirmed by skin biopsy. The child was managed with systemic methotrexate and topical mid-potent corticosteroids. The response to the standard treatment was good.

Case 3

A 4 year old boy presented with pink scaly skin lesions for the past 6 months on the right upper limb. On examination, erythematous scaly plaques were seen over the extensor surface of the right upper limb in a linear pattern. [Figure 2.B] Few isolated scaly plaques were seen over the left upper limb and right shoulder. Auspitz's sign was positive. A diagnosis of superimposed linear psoriasis was made. The child was subjected to skin biopsy and the histopathology was conclusive to the diagnosis of psoriasis. The child was managed with topical mid-potent corticosteroids and the response was good.

Case 4

An 8 year old girl presented with multiple red scaly skin lesions over her chest, back and thighs for the past 3 months. There was no H/o recent Fever/ URI. On examination, s. Auspitz's sign was positive. On closer look, the individual plaques were arranged in multiple

linear patterns corresponding to the lines of Blaschko. [Figure 2.C] Thus a diagnosis of superimposed linear psoriasis was made. Skin biopsy was done and was conclusive to the diagnosis of psoriasis. The child was managed with systemic Methotrexate and topical Mid-potent corticosteroid. The response was good.

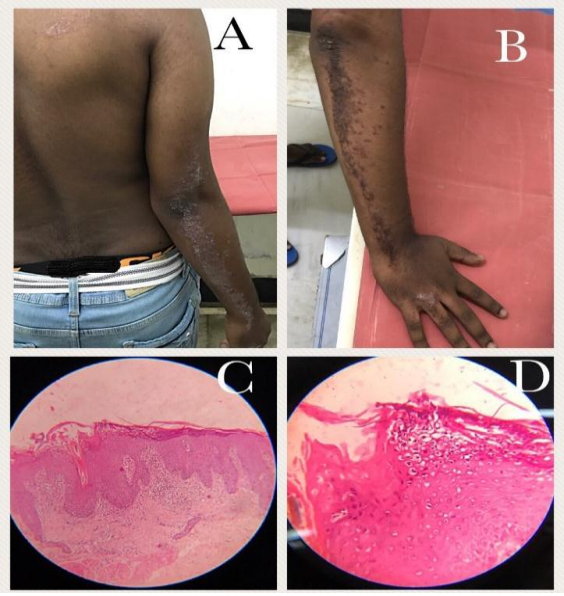

Figure 1: A. Erythematous scaly psoriatic plaques in a linear pattern on the right upper limb extending up to back. B. Resolving skin lesions at 6 weeks of treatment in the same patient. C. Photomicrograph at low power (10 X) showing typical features of psoriasis. D. Photomicrograph at high power (40 X) showing Munro's microabscess in the stratum corneum.

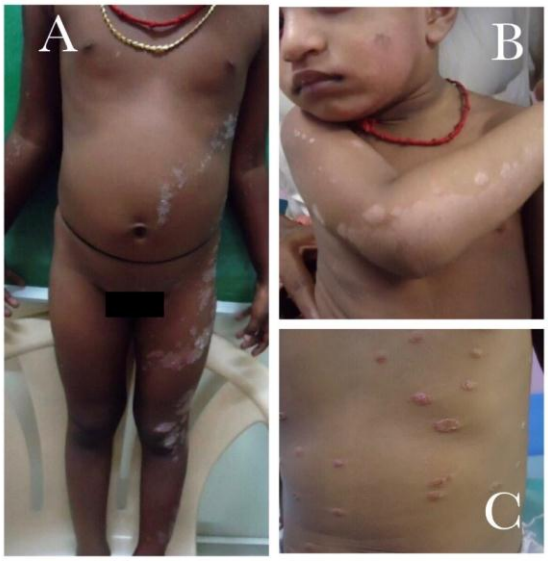

Figure 2: A. Multiple silvery white scaly psoriatic plaques over her right upper limb, left side of her abdomen, left thigh and left leg in a linear pattern. B. Erythematous scaly psoriatic plaques seen over the extensor surface of the right upper limb in a linear pattern C. Multiple well defined erythematous scaly psoriatic plaques arranged in Blaschkoid pattern.

DISCUSSION

Linear psoriasis is reported as a rare entity. It commonly occurs over the limbs and usually follows Blaschko's lines. It is common in children but can occur at any age. The exact incidence is not known as only a handful of cases are reported so far. True linear psoriasis with the absence of psoriatic plaques elsewhere is extremely rare with only a few cases reported in the literature.[3]

The aetio-pathogenesis was explained by Happle as crossing over of predisposing heterozygous genes during early embryogenesis resulting in homozygous state in a daughter cell. This process of somatic recombination (mosaicism) produces a homozygous daughter cell which acts as stem cell for the clone proliferating in a linear pattern along the embryonic lines of fusion. The genetic predisposition with environmental insults added in later life leads to development of skin lesions in a linear pattern.[4]

Superimposed linear psoriasis is relatively a new terminology coined to describe the cases with the development of non-linear psoriatic plaques at the usual sites of predilection, which is usual in most of the cases diagnosed with linear psoriasis.[5,6]

Clinically and histologically, the skin lesions are indistinguishable from that of psoriasis vulgaris except for its distribution. Association with nail pitting and psoriatic arthritis is reported. Co-existence of linear psoriasis with Conradi-Hunermann-Happle syndrome and Porokeratotic eccrine ostial and dermal duct nevus (PEODDN) is reported.[7,8]

The main differential diagnosis is inflammatory linear verrucous epidermal naevus (ILVEN), it differs clinically from linear psoriasis by a more eczematous, sometimes psoriasiform papules with intense pruritus and histologically by areas of hypergranulosis with orthokeratotic hyperkeratosis alternating with areas of agranulosis with parakeratotic hyperkeratosis.[9] Other differentials include linear lichen planus, lichen striatus, linear porokeratosis.

Response to routine anti-psoriatic treatment is usual. Topical dithranol, corticosteroids, phototherapy; systemic methotrexate are all found to be useful in the management of linear psoriasis.

CONCLUSION

Linear psoriasis is a rare entity as reported in the literature. But we encountered four such cases. Considering its uncommon occurrence and looking forward for such classical and superimposed cases, may get the recognition to what it deserves.

ACKNOWLEDGEMENT

None.

CONFLICT OF INTEREST

The authors declare that they have no conflict of interest.

REFERENCES

1. Molho-Pessach V, Schaffer JV. Blaschko lines and other patterns of cutaneous mosaicism. Clinics in dermatology, 2011 Apr 30; 29(2): 205-25.
2. Russell B. Psoriasis zosteriformis. British Journal of Dermatology, 1950 Jul 1; 62(7-8): 314-6.
3. Singh N, Noorunnisa N. Linear psoriasis: A rare presentation. Indian Dermatology Online Journal, 2012; 3(1): 71-73.
4. Happle R. Somatic recombination may explain linear psoriasis. Journal of medical genetics, 1991 May; 28(5): 337.
5. Happle R. Superimposed segmental manifestation of polygenic skin disorders. Journal of the American Academy of Dermatology, 2007 Oct 31; 57(4): 690-9.
6. Seitz CS, Garbaravičienė J, Bröcker EB, Hamm H. Superimposed linear psoriasis: differential therapeutic response of linear and nonlinear lesions. Clinical and experimental dermatology, 2009 Jul 1; 34(5).
7. Bruch D, Megahed M, Majewski F, Ruzicka T. Ichthyotic and psoriasiform skin lesions along Blaschko's lines in a woman with X-linked dominant chondrodysplasia punctata. Journal of the American Academy of Dermatology, 1995 Aug 1; 33(2): 356-60.
8. Yu HJ, Ko JY, Kwon HM, Kim JS. Linear psoriasis with porokeratotic eccrine ostial and dermal duct nevus. Journal of the American Academy of Dermatology, 2004 May 31; 50(5): 81-3.
9. Brinca A, Santiago F, Serra D, Andrade P, Vieira R, Figueiredo A. Linear psoriasis–A case report. Case reports in dermatology, 2011; 3(1): 8-12.