

DYSCHROMATOSIS UNIVERSALIS HEREDITARIA**Dr. Astuty Apurwa (MBBS), Dr. Nandita Patel (MBBS)*, Dr. Nitin Nadkarni (MD DVD) and Dr. Sharmila Patil (MD DDV)**

Department(s) and Institution(s): Department of Dermatology, Venerology and Leprosy, Dr. D. Y. Patil Hospital, School of Medicine, Nerul, Navi Mumbai, Maharashtra, India.

Corresponding Author: Dr. Nandita Patel (MBBS)

Department(s) and Institution(s): Department of Dermatology, Venerology and Leprosy, Dr. D. Y. Patil Hospital, School of Medicine, Nerul, Navi Mumbai, Maharashtra, India.

Article Received on 08/07/2017

Article Revised on 28/08/2017

Article Accepted on 18/08/2017

ABSTRACT

Dyschromatosis universalis hereditaria is a rare autosomal dominant genodermatosis seen most commonly in Japan. It may sometimes be inherited as autosomal recessive pattern, predominant in females. The spectrum of the diseases includes dyschromatosis universalis hereditaria (DUH), dyschromatosis symmetrica hereditaria (DSH/acropigmentation of Dohi) and a segmental form called as unilateral dermatomal pigmentary dermatosis (systemic involvement). It is often characterized by hypo- and hyperpigmented asymptomatic macules, distributed symmetrically on the extremities. Histological findings are thinning of epidermis with increased basal pigmentation and few macrosomes. Papillary dermis showed somewhat coarse collagen and perivascular lymphomonocytic infiltrate. Hereby, we report a rare case of DUH in male with autosomal recessive inheritance pattern and no systemic complains.

KEYWORD: Dyschromatosis symmetric hereditaria, genodermatosis, Dyschromatosis universalis hereditaria.**INTRODUCTION**

Dyschromatoses are rare forms of genodermatoses characterized by both hypopigmented and hyperpigmented macules of various shapes and size (generally smaller in size). The spectrum of the diseases includes dyschromatosis universalis hereditaria (DUH), dyschromatosis symmetrica hereditaria (DSH/acropigmentation of Dohi) and a segmental form called as unilateral dermatomal pigmentary dermatosis. DUH was initially reported in 1933 by Ichikawa and Hiraga^[1] in Japan but subsequent cases from different parts of the world have also been reported. It is often characterized by hypo- and hyperpigmented asymptomatic macules distributed symmetrically on the extremities. The distribution is generalized in DUH while it is localized to acral areas (dorsum of palms and feet) in DSH.

Here in, we report a rare case of dyschromatoses universalis hereditaria (DUH).

CASE REPORT

A 25 years old male, born out of a non-consanguineous marriage, presented with multiple black and white coloured lesions on his body since 4 years. No history of similar lesions in any family members.

The lesions were asymptomatic and started initially in axilla (freckles like) and gradually increased in number

and involved the entire body surface area. There were no other systemic complaints.

Cutaneous examination revealed multiple, discrete, symmetrically distributed, small (0.5-1 cm), round to oval shaped hypopigmented and hyperpigmented macules on extremities (Figure I), axilla (Figure II), groins, dorsum of hands and feet with relative sparing of trunk, palms and soles, hair, oral mucosa and genitals. Nails (few) showed blackish longitudinal lines. No evidence of atrophy and telangiectasia. Deep dermal tenderness was negative.

Routine investigations like complete blood count, urine (routine and microscopy), renal function test and liver function test were normal.

On the basis of history and cutaneous examination, we considered the differential diagnosis as dyschromatosis universalis hereditaria, Xeroderma pigmentosum, Dowling Degos disease, Galli Galli and Kitamura disease.

Biopsy was done to confirm the diagnosis. Histopathology of hyperpigmented macule showed:

Thinning of epidermis with increased basal pigmentation and few macrosomes. Papillary dermis showed somewhat coarse collagen and perivascular lymphomonocytic infiltrate (Figure III, Figure IV).

On the basis of histopathology and clinical findings the diagnosis was confirmed as DUH.

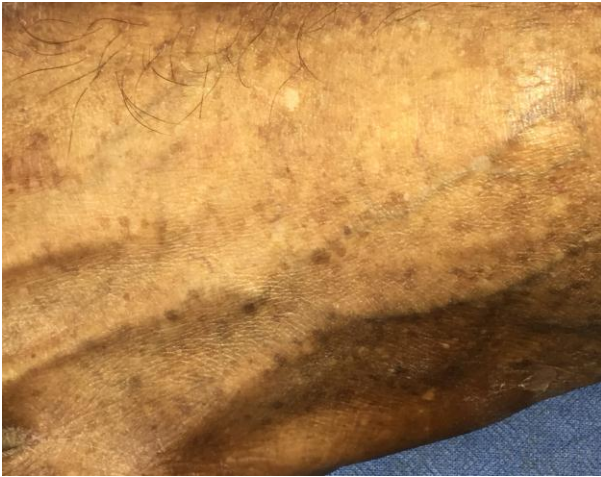

Figure-1.

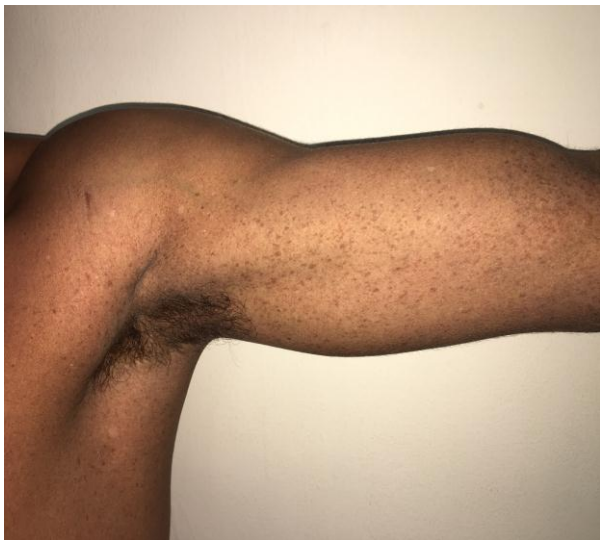

Figure-2.

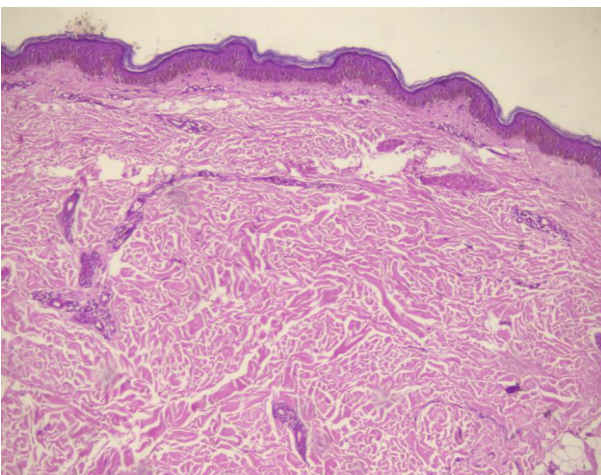


Figure-3.

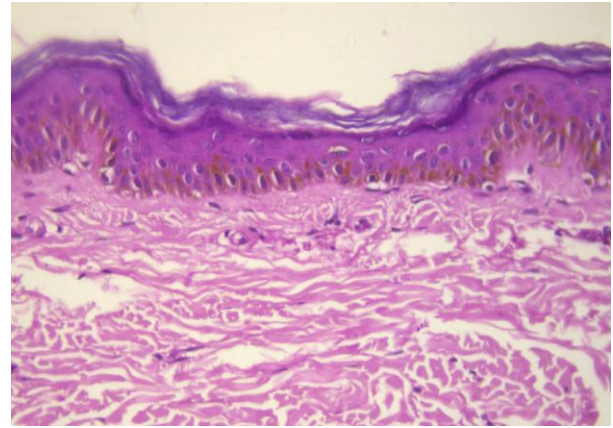


Figure-4.

DISCUSSION

DUH is a rare genodermatosis which has been most often reported in Japan. Although majority of the cases have been inherited as autosomal dominant pattern, a few have shown autosomal recessive pattern. Interestingly, our patient had no similar family history.

Two most common types have been described, based on the distribution of the lesion:

- 1) DUH: Hyperpigmented and hypopigmented (mixed) macules present all over body.^[2]
- 2) DSH (Dyschromatosis Symmetrica Hereditaria): Macules present on aural areas.^[3]

Total 37 cases were reported in Japan, of which 22 were females and 15 were males. 82% of the patients had clinical symptoms before the age of 6 years.^[1] DUH may be associated with abnormalities of dermal connective tissue, nerve tissue, or be associated with other systemic complaints.^[4,5] Palms and soles are relatively spared. But, to our interest, our patients started developing lesions at the age of 21 years (after adolescence) with no other systemic complaints.

Lesions of DUH have to be differentiated clinically and histopathologically from xeroderma pigmentosum, since primarily photo-exposed area is most commonly affected in both the disorders. The lesions of DUH follows a benign course with no atrophy and telangiectasia. It doesn't worsen with age.^[6] Other differential diagnosis to be considered are DSH, Xeroderma pigmentosum, Dyskeratosis congenital, generalized Dowling Degos, incontinentia pigmenti, Kitamura disease, Galli Galli disease.^[7]

The histopathological findings of the lesions are suggestive of increase or decrease melanin pigmentation in basal layer (depending on the lesion from where biopsy is taken). Sometimes, pigment incontinence is also seen. Our patient's histopathological findings were increased in melanin pigmentation with macrosomes at few places. NBUVB can be tried for better cosmetic results.

DUH is reported worldwide in increasing frequency because of its resemblance with xeroderma pigmentosum

(which can be differentiated clinically). Very few cases have been reported from India.^[1,6,8,9,10] Thus, we are reporting an adult onset, autosomal recessive DUH with no systemic complains for its rarity.

Conflicting Interest (If present, give more details)

None.

ACKNOWLEDGEMENT

None.

REFERENCES

1. Hari Kishan Kumar Yadalla, Srivalli Pinninti, and Anagha Ramesh Babu. Dyschromatosis universalis hereditaria: Infrequent genodermatoses in India. *Indian J Hum Genet*, 2013 Oct-Dec; 9(4): 487-90.
2. Ichikawa T, Higara Y. About a pigmentary anomaly unprecedented. *Jon J Dermatol*, 1933; 34: 360-4.
3. Toyama I. Dyschromatosis symmetric hereditaria. *Jon J Dermatol*, 1929; 29: 95-6.
4. Miyamura Y, Suzuki t, Kono M, Inagaki K, Ito S, Suzuki N, et al. Mutations of the RNA-specific adenosine deaminase gene(DSRAD) are involved in dyschromatosis symmetric hereditary. *Am J Hum Genet*. 2003; 73: 693-9.
5. Suzuki N, Suzuki T, Inagaki K, Ito S, Kono M, Fukai K, et al. Mutation analysis of the ADAR1 Gene in Dyschromatosis Symmetrica Hereditaria and genetic differentiation from both Dyschromatosis Universalis Hereditaria and Acropigmentatio Reticularis. *J Invest Dermatol*, 2005; 124: 1186-92.
6. Merino de Paz N, rodriguez-Martin M, Cortreras Ferre P, pestana-Eliche M, Martin-Herrera A, Noda-Cabrera A. Photoletter to the editor: Dyschromatosis universalis hereditaria: An infrequently occurring entity in Europe. *J Dermatol Case Rep.*, 2012; 3: 96-7.
7. Nuber UA, Einschert S, Mundlos S, Tauber I. Dyschromatosis universalis hereditaria: Familial case and ultrastructural skin investigation. *Am J Med Gen A.*, 2004; 125A: 261-6.
8. Rai R, Kaur I, Handa S, Kumar B. Dyschromatosis universalis hereditaria. *Indian J Dermatol Venerol Leprol*, 2000; 66: 158-9.
9. Naik CL, Singh G, Rajashekar TS, Okade R. Dyschromatosis universalis hereditaria. *Indian J Dermatol*, 2009; 54: 74-5.
10. Kenani N, Ghariani N, Denguezli M, Sriha B, Belajouza C, Nouira R. Dyschromatosis universalis hereditaria: Two cases. *Dermatol Online J.*, 2008; 14: 16.