

**EXTRA ADRENAL PARAGANGLIOMA**Dr. Tongbram Soni Devi<sup>1</sup> and Dr. P. Karkuzhali<sup>2</sup><sup>1</sup>1<sup>st</sup> Year PG, Department of Pathology, Sree Balaji Medical College and Hospital, Chennai.<sup>2</sup>Prof. and HOD, Department of Pathology, Sree Balaji Medical College and Hospital, Chennai.**\*Corresponding Author: Dr. Tongbram Soni Devi**1<sup>st</sup> Year PG Department of Pathology, Sree Balaji Medical College, Chrompet, Chennai, Tamilnadu.

Article Received on 12/08/2017

Article Revised on 03/10/2017

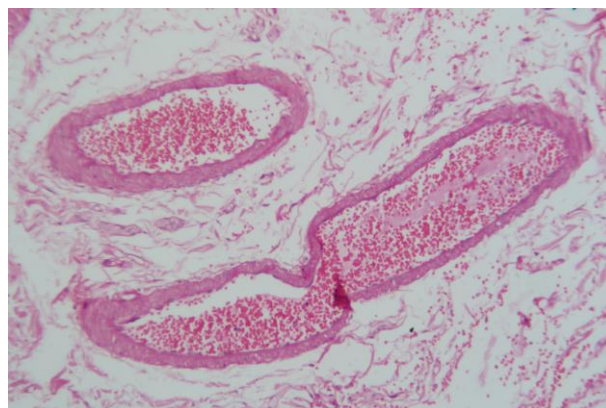
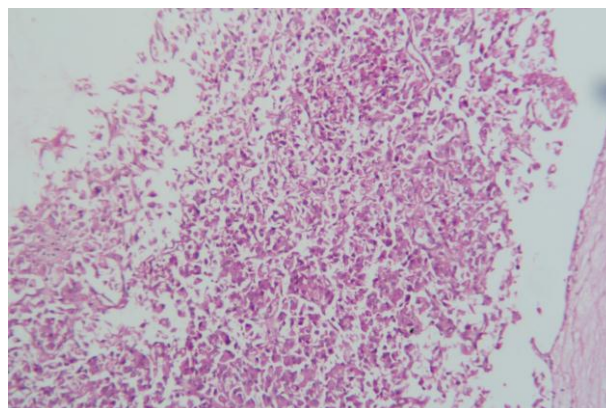
Article Accepted on 24/10/2017

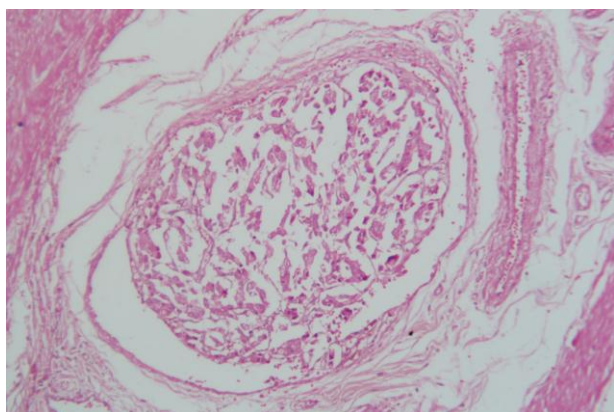
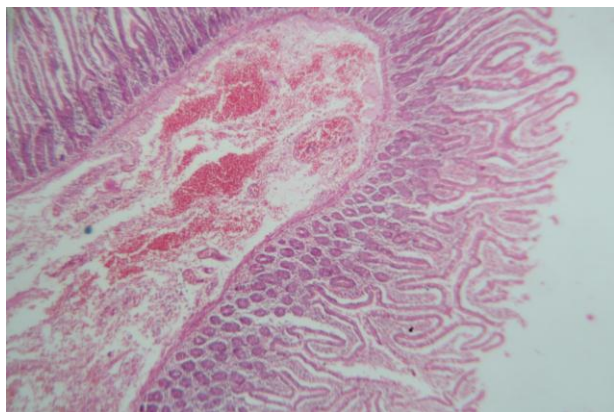
**ABSTRACT**

Extra adrenal paraganglioma are rare endocrine tumours arising from embryonic cell crest. Paraganglioma represents only 10% of cromaffin tissue tumors and those arising from the mysentry seem to be a rare occurrence. Extra adrenal paraganglioma most commonly develop adjacent to the aorta, particularly the area corresponding to the organ of Zuckerkandl. Funtional paraganglioma secrete catecholamines which clinically may present with headache, sweating & palpitation & symptoms of hypertension. Non functional may remain silent and present with vague symptoms like pain abdomen or insidiously enlarging palpable mass or pain related to the local growth of a tumour mass. We hereby report a case of 51 year old man complaints of diffuse pain abdomen x 1 week. Post operative Diagnosis-?GIST. Laprotomy was done with en block dissection of tumour along with 3<sup>rd</sup> & 4<sup>th</sup> part of duodenum with proximal jejunum with duodenojejunostomy & gastrojuenostomy.

**KEYWORDS:** Paraganglioma, cromaffin, atecholamines.**CASE REPORT**

A 51 year old man complaints of diffuse pain abdomen x 1 week. No vomiting, No jaundice. No other complaints. O/E-P/A –Soft, No palpable mass, BS(+). Post operative Diagnosis-?GIST. Procedure done-Laprotomy with en block dissection of tumour along with 3<sup>rd</sup> & 4<sup>th</sup> part of duodenum with proximal jejunum with duodenojejunostomy & gastrojuenostomy specimen-Tumour along with 3<sup>rd</sup> & 4<sup>th</sup> part of duodenum with proximal jejunum. H/O abdominal pain x 1 week. CT scan showed possibility of primary retroperitoneal neoplasm, exophytic neoplasm (from iv part of duodenum), exophytic neoplasm from uncinated process of pancreas. Investigation results for HB-14.7, LFT-Bilirubin (Total)-1.0 Bilirubin (Direct)-0.3 Bilirubin (Indirect)-0.7 SGOT-24, SGPT-19, ALP-58, Amylase - 62, Lipase-38. **Grossly**-Received resected loop of small intestine with attached fat measuring 80cm in length. 2 tumour masses are attached at the duodenal end. 1<sup>st</sup> mass measuring 10 x 5 x 5 cm. E/S of areas of haemorrhage. C/S- multiple cyst areas with gelatinous material (cystic degeneration). It was gritty to cut,? calcification. 2<sup>nd</sup> mass measuring 10 x 5 x 5cm tumour with attached fat. C/S-cystic areas with gelatinous material (cystic degeneration) measuring 3.5 x 3.5cm rest of the mass shows fatty tissue. It was gritty to cut,? calcification. E/S of the rest of the intestine appears normal. A small loop(bit) of intestine sent seperately in the same container measuring 2 cm in length.





**Microscopy:** Multiple section studied shows small intestinal mucosa & muscle layer overlying a cellular neoplasm composed of oval to polygonal cells with dark staining pleomorphic nuclei & abundant cytoplasm showing intracytoplasmic microvacuolation arranged in lobules divided by hyalinised fibrous septa. Tumour cells are arranged in sheets, in places nest cords & ribbons & also surrounding blood vessels & blood spaces, Mitotic figures & tumour emboli are seen. Resected margins & separately sent loop of intestine show normal histology. Areas of calcification are seen in hyalinised fibrous septa. Island of tumour tissue invade in to the muscle layer of other small intestine. Thin vessels are seen in the stroma. Picture is suggestive of PARAGANGLIOMA.

## DISCUSSION

Extra adrenal paranglioma can occur in individuals at any age, although most arise in the fourth or fifth decades of life. Paranglioma are tumours which arise in extra adrenal paranglia. Majority of the patients with extra-adrenal abdominal paranglioma presented with complaints of abdominal pain and/or a palpable abdominal mass, however patients may be asymptomatic. Symptoms such as hypertension, flushing, sweating, headache, diaphoresis, anxiety, tachycardia or palpitations are symptoms reported in patients with increased catecholamine secretion in functional tumours. Even though imaging techniques are helpful, diagnoses of extra abdominal or intra abdominal parangliomas can only be done with careful histological. CT scan is useful for diagnosis while MRI has the highest

sensitivity in detection of extra-adrenal parangliomas as well as pheochromocytomas. Paranglioma is a rare neuroendocrine neoplasm. According to WHO classification of neuroendocrine neoplasm they arise from the chromaffin negative cells derived from embryonic negative cells. They belong to Group II tumours as categorized by Wick in updated terminology for neuroendocrine neoplasm. In the fetal life, paranglionic tissue is derived from pheochromoblasts, highly concentrated at a level extending from the root of the inferior mesenteric artery or the renal artery to the aortic bifurcation, known as the organ of Zuckerkandl. In contrast, in the adult, the mature adrenal medulla replaces the involuted organ(s) of Zuckerkandl to form the largest collection of paranglionic tissue. Extraadrenal parangliomas of the abdomen arise predominantly from paranglia located in the retroperitoneum. These paranglia are symmetrically distributed along the abdominal aorta and are closely related to the sympathetic nervous system. Treatment is surgical resection. Most of the times significant mesentery has to be removed hence resection of the bowel is inevitable and anastomosis is required. Adjunctive therapies like Radiotherapy and chemotherapy can be considered palliative in malignant cases and unresectable cases. A correlation between clinical and histological distinction between benign and malignant tumours is difficult. Only presence of metastasis can prove malignancy. Neither local nor distant metastasis are reported in parangliomas of mesentery of small intestine till date. In retroperitoneal tumours 5yrs and 10yrs survival rates are 75% and 45% respectively<sup>4</sup>. But the prognosis for paranglioma in the mesentery of small intestine is is not reported till date. However long term follow up after surgical resection is advised.

## CONCLUSIONS

Extra adrenal paranglioma of small intestine ia a very rare disease. It is fascinating and challenging to medical fields because it carries a high risk of morbidity and mortality if it is undiagnosed or untreated. Thus pre-operative assessment, intra-operative monitoring, surgical skill and finally pathological diagnosis achieve the successful outcome. Long term follow-up is mandatory, as the tumor is prone to recur and to metastasize.

## REFERENCE

1. An Unusual Mesenteric Tumor 'Paranglioma': A Case Report Zeynep Ozkan,<sup>1,\*</sup> Cengizhan San Ozdemir,<sup>1</sup> Gunay Yasar,<sup>2</sup> Onder Altas,<sup>1</sup> Mustafa Koc,<sup>3</sup> Yeliz Gul,<sup>4</sup> and Emre Durdag<sup>5</sup>. Iran Red Crescent Med J. 2014 Dec; 16(12): e16837. Published online 2014 Dec 14. doi: 10.5812/ircmj.16837 PMID: PMC4341248.
2. Extraadrenal Parangliomas of the Body: Imaging.) August 2006, Volume 187, Number2 Ki Yeol Lee<sup>1</sup>, Yu-Whan Oh<sup>1</sup>, Hyung Jun Noh<sup>1</sup>, Yu Jin

- Lee<sup>1</sup>, Hwan-Seok Yong<sup>1</sup>, Eun-Young Kang<sup>1</sup>, Kyeong Ah Kim<sup>1</sup> and Nam Joon Lee<sup>1</sup>. American Journal of Roentgenology, 2006; 187: 492-504. 10.2214/AJR.05.0370.
3. Malignant paraganglioma of the mesentery: a case report and review of literature Michael Chetrit, Pierre Dubé, Virginie Royal, Guy Leblanc and Lucas Sideris Email author *World Journal of Surgical Oncology* 2012;10:46 DOI: 10.1186/1477-7819-10-46 © Chetrit et al; licensee BioMed Central Ltd. 2012 Published: 23 February 2012.
  4. Mesenteric Paraganglioma A Case Report and Review of the Literature Shabnam Jaffer, MD and Noam Harpaz, MD From the Department of Pathology, Mount Sinai Medical Center, New York, NY Reprints: Shabnam Jaffer, MD, The Mount Sinai Medical Center, One Gustave L. Levy Place, Department of Pathology, Box 1194, New York, NY 10029. *Archives of Pathology & Laboratory Medicine*, March 2002; 126(3).
  5. Paraganglioma of Mesentery of Jejunum—A Case Report and Review of Literature By Dr. Raghuveer M N, Prof. G Siddesh, Dr. Girish T U & Dr. Mohammed Raza JSS University, India *Global Journal of Medical Research: I Surgeries and Cardiovascular System*, 14(4): Version 1.0 Year 2014 Global Journals Inc. (USA) Online ISSN: 2249-4618 & Print ISSN: 0975-5888.
  6. Paraganglioma: A diagnostic dilemma Pakistan Medical Association Numan Jahangir (Fourth Year Medical Student, Ziauddin Medical College, Karachi.) Bushra Shirazi (Department of Surgery, Ziauddin Medical College, Karachi.) *Journal of Pakistan*.
  7. Pheochromocytoma and Paraganglioma: An Endocrine Society Clinical Practice Guideline Jacques W. M. Lenders, Quan-Yang Duh, Graeme Eisenhofer, Anne-Paule Gimenez-Roqueplo, Stefan K. G. Grebe, Mohammad Hassan Murad, Mitsuhide Naruse, Karel Pacak William F. Young, Jr, 2014; 99(6): 1915-1942. Published: 16 November 2016.
  8. Mesenteric paraganglioma: Report of a case Takeshi Fujita, Kinji Kamiya, Yoshiaki Takahashi, Shinichiro Miyazaki, Ichirota Iino, Hirotohi Kikuchi, Yoshihiro Hiramatsu, Manabu Ohta, Satoshi Baba, and Hiroyuki Konno *World J Gastrointest Surg*, 2013 Mar 27; 5(3): 62–67. Published online 2013 Mar 27. doi: 10.4240/wjgs.v5.i3.62 PMID: PMC3615306.
  9. Case Report Retroperitoneal Extra-Adrenal Paraganglioma Damle Rajshri P\*, Suryawanshi Kishor H\*, Patil Tushar B\*\*, Dravid N. V\*, Newadkar D.V\*, Gadre A.S\* \*Department of Pathology, \*\*Department of Surgery, A.C.P.M. Medical College, Dhule. Maharashtra. India, *Int. j. pathol*, 2015; 13(3): 128-132 128.
  10. Malignant paraganglioma of the mesentery: a case report and review of literature, Michael Chetrit, Pierre Dubé, Virginie Royal, Guy Leblanc and Lucas Sideris Email author *World Journal of Surgical Oncology*, 2012; 10: 46 <https://doi.org/10.1186/1477-7819-10-46> © Chetrit et al; licensee BioMed Central Ltd. 2012 Published: 23 February 2012.
  11. Paraganglioma of the Mesenterium: a Case Report Švajdler M. ml., Bohuš P., Závacký P. Voľanská M.1, Repovský A., Juskaníčová E. Department of Pathology, Louis Pasteur Faculty Hospital, Košice 11st Department of Surgery, Louis Pasteur Faculty Hospital, Košice 2 Department of Radiodiagnostics, A. Leňo Hospital, Humenné 3 Department of Oncology, A. Leňo Hospital, Humenné Slovak Republic. *Čes.-slov. Patol.*, 2007; 43(4): 153–156.
  12. Mesenteric Paraganglioma: Report of a Case Akitoshi Kudoh, Yoshihiro Tokuhisa, Katsuhiko Morita, Sakurao Hiraki, Shintarou Fukuda, Nobuo Eguchi, Takako Iwata, Department of Surgery, Ube Central Hospital, Ube, Yamaguchi 755-0151, Japan 2 Department of Laboratory Sciences, Faculty of Health Sciences, Yamaguchi University, School of Medicine, Yamaguchi, Japan *Surgery Today*, July 2005; 35(7): 594–597.
  13. The Japanese Journal of Gastroenterological Surgery, A Case of Mesenteric Paraganglioma Kentaro Matsumoto<sup>1)</sup>, Keiji Hirata<sup>1)</sup>, Shuichi Kanemitsu<sup>1)</sup>, Satoshi Kawanami<sup>2)</sup>, Takatoshi Aoki<sup>2)</sup>, Naoki Nagata<sup>1)</sup>, Hideaki Itoh<sup>1)</sup> 1) Department of Surgery 1, University of Occupational and Environmental Health 2) Department of Radiology, University of Occupational and Environmental Health, 2006; 39(1): 84-89.
  14. *BMJ Case Rep.* 2014; 2014: bcr2013203425. Published online 2014 Feb 20. doi: 10.1136/bcr-2013-203425 PMID: PMC3931965 Case Report Functional paraganglioma Gokulakrishnan Balasubramanian<sup>1,2</sup> and Vallikantha Nellaippan.
  15. *Transl Gastroenterol Hepatol.* 2016; 1: 58. Published online 2016 Jul 18. doi: 10.21037/tgh.2016.06.01 PMID: PMC5244753 A rare case of retroperitoneal paraganglioma—case report and literature review Peng Li and Dongbing Zhao.