

**THE TRANSBASAL DEROME APPROACH TO ANTERIOR SKULL BASE:
REFLECTIONS OF THE PAST AND IMPLICATIONS FOR THE FUTURE****Dr. Jaspreet Singh Badwal***

Head and Neck Surgeon, FUICC (Europe).

Recently completed UICC Technical Fellowship in Head and Neck Surgery and Oncology from Netherlands Cancer Institute, Amsterdam, Netherlands.

***Corresponding Author: Dr. Jaspreet Singh Badwal**

Head and Neck Surgeon, FUICC (Europe) Recently completed UICC Technical Fellowship in Head and Neck Surgery and Oncology from Netherlands Cancer Institute, Amsterdam, Netherlands.

Article Received on 17/09/2017

Article Revised on 08/10/2017

Article Accepted on 29/10/2017

ABSTRACT

The tumours of anterior skull base may involve the paranasal sinuses, orbit and clivus. Surgical management of such pathology is often difficult and requires the transbasal or Derome approach to anterior skull base. The indications for this surgery are very broad and include tumours, traumatic lesions, CSF (cerebrospinal fluid) fistulas, congenital abnormalities and some vascular lesions. Lesions extending lateral to the internal carotid artery, cavernous sinus, petroclival region and posterior inferior portion of the clivus can be removed by a combined approach in the same or a second operative procedure.

KEYWORDS: Transbasal approach; anterior skull base; Derome approach; bifrontal craniotomy; craniofacial resection.

INTRODUCTION

The tumours of anterior skull base may involve the paranasal sinuses, orbit and clivus. Surgical management of such pathology is often difficult and requires a multidisciplinary team of neurosurgeon, maxillofacial / craniomaxillofacial surgeon and a head and neck surgeon. The transbasal or Derome approach to anterior skull base was developed by Tessier et al^[1] for treatment of craniofacial abnormalities. Later Ketcham^[2] in 1963 described a combined intracranial and extracranial approach to the anterior skull base for craniofacial resection of malignant tumours. Derome^[3,4] modified and used the approach for tumours extending to anterior and middle skull base. Subsequently, several modifications were developed with versatile names, such as the frontobasal, transbasal, subcranial and craniofacial approach.^[5-9] Since these early reports, several authors have extended the indications and modified this surgical approach.^[8-13] Having been established as a reliable surgical technique through many decades, the procedure has become the approach of choice for tumours involving the craniofacial region and can be classified as extradural, intradural or combined.^[14]

Indications

The indications for this surgery are very broad and include tumours, traumatic lesions, CSF (cerebrospinal fluid) fistulas, congenital abnormalities and some vascular lesions.^[9,11,15-17] Lesions of the midline that involve the paranasal sinuses, orbit, anterior cranial

fossa, anterior portion of clivus and sellar and suprasellar regions can be surgically managed using this approach. The procedure allows wide exposure from the frontal sinus down to the foramen magnum / C1 region.^[4,14] Lesions extending lateral to the internal carotid artery, cavernous sinus, petroclival region and posterior inferior portion of the clivus can be removed by a combined approach in the same or a second operative procedure.^[9,11,14]

Surgical Considerations and Operative Technique**Surgical Considerations**

The *extradural* subcranial approach is used for extradural tumours such as osteomas, fibrous dysplasia, chordomas, and chondrosarcomas, malignant tumours of the paranasal sinuses, traumatic lesions, CSF fistula, infections, and congenital abnormalities. Small dural lacerations (traumatic lesions) are repaired through this procedure.

The *intradural* subcranial approach is indicated when the lesion remains solely intradural. The indications include craniopharyngiomas, large pituitary adenomas, olfactory groove and tuberculum sellae meningiomas, and others. The *combined* subcranial approach is used when the tumour invades the skull base dura and bone and its removal establishes a communication between the intradural space and the paranasal sinuses. Esthesioneuroblastomas, invasive meningiomas and

malignant processes are examples of tumors that may require this approach.

Operative Technique

The Approach

General anesthesia with oral endotracheal intubation is used in all patients. Tracheostomy is rarely used. The oral cavity is packed with gauze. Both the face and the head are prepared with povidone-iodine solution. Antibiotic therapy, beginning the night before, is routinely used and continued for 3 days after the surgery. The patient is placed in the dorsal decubitus position with the neck extended and the head secured in a head holder above heart level. A bicoronal incision is made beginning anterior to the tragus at the level of the zygoma. The skin flap is dissected in the subperiosteal plane and turned down anteriorly at level of the orbital rims and glabella. The galea and periosteum are incised at a level higher than the skin incision to obtain a very long flap. The supraorbital foramen is identified and the supraorbital nerve and artery are preserved. This foramen is frequently incomplete and the nerve and artery are dissected free with the pericranium. Sometimes the foramen is opened using a small osteotome and the neurovascular pedicle released with the bicoronal flap.

A large galea-periosteum flap that includes a small portion of the anterior temporalis fascia is dissected, remaining attached to the supraorbital region. It is used to cover the floor of the anterior fossa, the paranasal sinuses and orbits to reconstruct the dura at the end of the operation. This flap is a modification of the traditional galea-periosteum flap because it includes the temporalis fascia. This large, vascularized flap is very useful for covering the whole anterior cranial fossa and supports the bone fragments used for reconstruction of the surgical defect in the anterior fossa (Fig. 1).

A bicoronal craniotomy is carried out: the frontal bone includes both orbital rims and a large portion of the orbital roof on both sides. Three bur holes are drilled: two holes are placed in the "key point" (after coagulating and dissecting a small portion of the temporalis muscle), 1 cm below the superior temporal line, in the temporal fossa, behind the lateral orbital rim (Fig. 2). The third bur hole is placed over the sagittal sinus approximately 6 cm from the nasion. A bur hole over the frontal sinus is avoided by cutting the bone in the region of the glabella with a small cutting bur or an oscillating saw (Fig. 3). The bur holes are connected using the Gigli saw or craniotome. The periorbita is bilaterally dissected from the orbital roof. The anterior two thirds of the orbital roof is cut using a small curved osteotome and high-speed drill. Both orbital roofs are connected with the opening in the nasion region using a high-speed drill. The bicoronal craniotomy bone is removed (Fig. 4). The frontal sinus mucosa is totally removed with a bur from its inner table. The frontal sinus is completely cranialized by removing the posterior wall of the sinus with rongeur and cutting burs. In cases in which the frontal sinus is

infiltrated by the tumour, this portion of the lesion can be easily resected at this point. At this stage of the operation, surgical variations are performed according to the histologic type and extension of the lesion.

Extradural Approach

The basal dura mater is detached from the anterior cranial fossa floor and crista galli. One or two olfactory nerves are sectioned, depending on the lesion's extension. The dura over the lamina cribrosa, ethmoid roof and orbit is elevated up to the planum sphenoidale and the anterior clinoid processes, exposing both optic nerves extradurally. The crista galli and the lamina cribrosa are removed using the high-speed drill and a fine leksell. If the lesion infiltrates the olfactory bulbs, they are resected intradurally. Possible dural lacerations during this dissection are sutured or grafted using temporalis fascia. Self-retaining retractors are positioned. This extradural approach completely exposes the anterior cranial base from orbit to orbit. It allows exposure of nasal septum, both nasal fossae and the nasopharynx. Removal of the facial portion of the lesion is often possible without any additional facial approach. The medial aspect of the orbit can be approached after removal of the lamina papyracea and ligation of the anterior and posterior ethmoid vessels. The optic nerve canal is identified and decompressed under the microscope using diamond burs and irrigation. The superior orbital fissure may be opened.

Both ethmoid sinuses can be totally removed and the sphenoid sinus is exposed by resection of the planum sphenoidale. Tumors in the sphenoid sinus region and in the clivus (midline) are removed using this procedure.

Some lesions (e.g., adenoid cystic carcinoma) may extend into the middle fossa, following the second branch of the trigeminal nerve (V2) into the gasserian ganglion. Extradural dissection of the floor of the middle fossa is carried out and the second division of the trigeminal nerve (V2) identified. In some cases, a small temporal craniectomy may be necessary to expose the third division of the trigeminal nerve (V3) after coagulation and cutting of the middle meningeal artery. The superior orbital fissure and the clinoid portion of the internal carotid artery are identified by extradural dissection with removal of the lateral aspect of the greater sphenoid wing and intradural drilling of the anterior clinoid process (Fig. 5). This gives access to the cavernous sinus and infratemporal fossa.

The sphenoid sinus can be entered in two ways: through a midline approach after removal of planum sphenoidale or laterally through the floor of the middle fossa between V2 (maxillary nerve) and V3 (mandibular nerve). The intersphenoid septum is resected with a rongeur and tumour in the sphenoid sinus and lower clivus can be removed with microsurgical techniques. Some lesions, such as chondrosarcomas and chordomas, may extend

down to the jugular foramen. The extradural portion of these tumours can be removed using this approach.

Intradural Approach

The subcranial approach is also used for intradural tumors like pituitary adenomas, craniopharyngiomas, meningiomas, chordomas, chondrosarcomas and others. In cases of severe craniofacial trauma with contusion or laceration of the frontal lobes, this procedure allows wide exposure for inspection of the intradural compartment and dural reconstruction.

After bilateral craniotomy involving orbital rims and frontal sinus cranialization, dural incision is performed over the fronto-orbital region and the superior sagittal sinus is double ligated and cut. Under the microscope, the anterior aspect of the sylvian fissure is opened to release CSF and reduce brain retraction. Both frontal lobes are elevated by gentle retraction, exposing the whole anterior fossa, the olfactory nerves, optic nerves, carotid arteries and the pituitary region. In cases of sellar lesions (e.g., craniopharyngiomas, pituitary adenoma and tuberculum sellae meningiomas) at least one olfactory nerve can be preserved.

Removal of the lesion in the sellar and parasellar region is possible after identification of the optic nerves and internal carotid arteries. An ultrasonic aspirator is used for the intracranial portion of the tumour. In some cases, such as in malignant lesions, the anterior portion of the cavernous sinus is invaded through the superior orbital fissure. This intracavernous portion of the tumour can be exposed and removed through this approach. The internal carotid artery is identified in the clinoid region by intradural removal of the anterior clinoid process after opening the superior orbital fissure. Resection of invaded internal carotid artery and nerves of the superior orbital fissure may be carried out in cases of malignancy. A preoperative balloon occlusion test is performed and if necessary, a bypass between the petrous portion or cervical portion of the internal carotid artery and the middle cerebral artery (M1 and M2 segments) can be performed using a saphenous vein graft.

Combined Approach

If necessary, the classic transfacial approach^[18] can be used in combination with the transbasal approach to extend the operation to include access to the maxillary sinus, pterygopalatine fossa, infratemporal fossa and middle cranial fossa (Fig. 6, 7). Also, the standard bifrontal craniotomy may be combined with the orbitozygomatic approach or temporal craniotomy to provide access to lesions extending to the cavernous sinus, sellar and parasellar areas (Fig. 8). The Weber-Fergusson incision is used for more malignant lesions in which a radical operation is necessary (e.g., for total maxillectomy including orbital exenteration and reconstruction). In cases of esthesioneuroblastomas, the dura is opened for resection of the olfactory bulbs, with intraoperative frozen-section histologic studies obtained

to ensure safe margins and removal of intradural tumour.¹⁹ Some aggressive meningiomas invade the floor of the anterior cranial base, the paranasal sinuses and the intradural compartment. Removal of the lower part (maxillary sinuses) of these lesions requires transfacial approaches. Aggressive pituitary adenomas may infiltrate the ethmoid and the sphenoid sinuses. In these cases, a combined subcranial-transfacial approach is also used. Reconstruction of dura and cranial base is one of the most important steps of this approach. Communication of the intradural compartment with the paranasal sinuses may cause CSF fistula and meningitis.

Reconstruction

Reconstruction of the large defect in the frontobasal approach is of paramount importance. The dura is sutured primarily whenever possible or a temporalis fascia graft is used. The modified pedicled galea-pericranium flap is then rotated to cover the whole anterior fossa. Reconstruction of large bone defects of the anterior fossa is necessary because of the resulting dead space and to avoid delayed meningoceles, encephaloceles and meningitis. Bone for this purpose is taken from the inner table of the frontal craniotomy bone. It is removed with an oscillating saw or small high-speed drill. In some cases, such as in children, it can be obtained from the iliac bone; this has the advantage of providing both cancellous and cortical bone. Over this flap, bone grafts from the inner table of the frontal bone are placed and covered with the temporalis fascia attached to the galea-pericranium flap.

Reconstruction of the supraorbital margins and orbital roofs is not necessary because they remain in the craniotomy in one piece. If they are infiltrated by the lesion and have to be removed, they can be reconstructed with iliac graft or with split rib graft. The nasal cavities and the oropharynx are packed with tetracycline-soaked gauze. This packing is left in place for 7 days.

For patients with a large defect of the anterior skull base, a spinal lumbar catheter for continuous CSF drainage is inserted. This system is usually removed 3 days after surgery. The bifrontal craniotomy is closed in routine fashion.

Legends for Figures

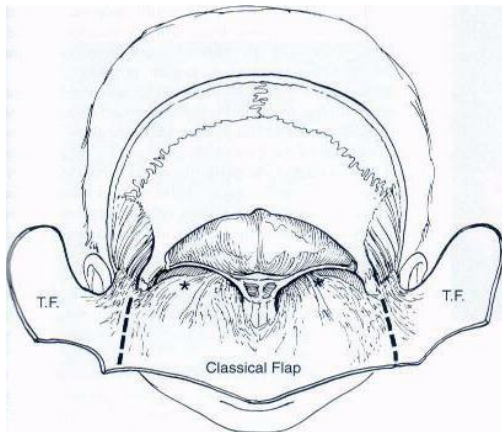


Fig. 1: Modified galea-periosteum flap. The temporal fascia (T.F.) remains attached to the "classic flap" (asterisks) periorbita.

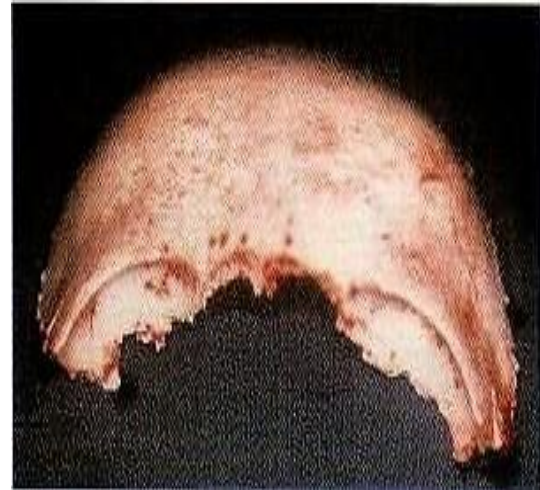

Fig. 4: Both orbital roofs are connected with the opening in the nasion region using a high-speed drill. The bicornal craniotomy bone is removed.

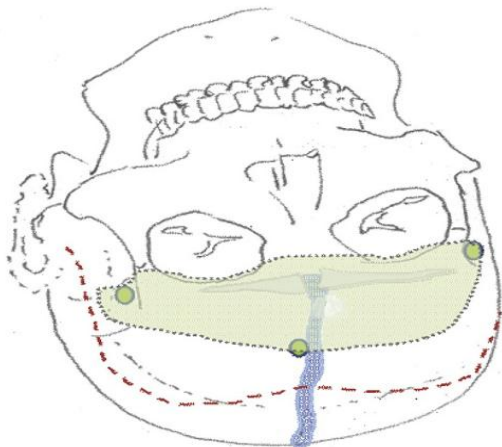


Fig. 2: Skin incision (red dashed line), craniotomy (gray dotted line), frontal sinus (gray filled space) and bur holes (green ovals) for bifrontal transbasal approach that is sometimes used with an orbitozygomatic approach.

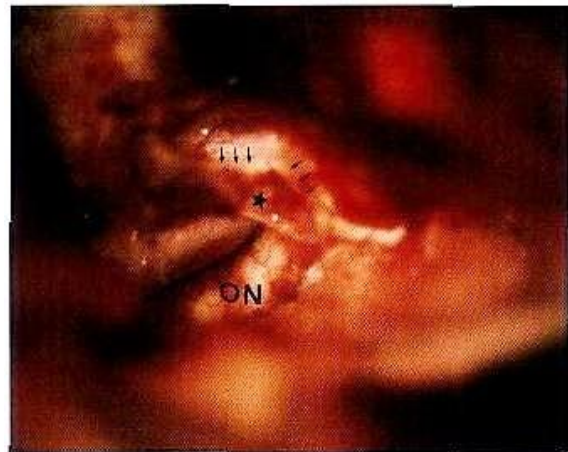


Fig. 5: Exposure of the clinoid portion of the internal carotid artery and dural ring around the vessel (asterisk). The anterior clinoid process was removed intradurally (arrows). ON, optic nerve.

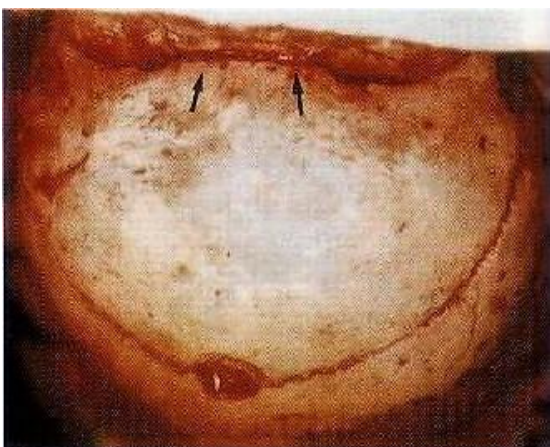


Fig. 3: Bicornal craniotomy. The bone in the region of the glabella is cut with an oscillating saw (arrows).

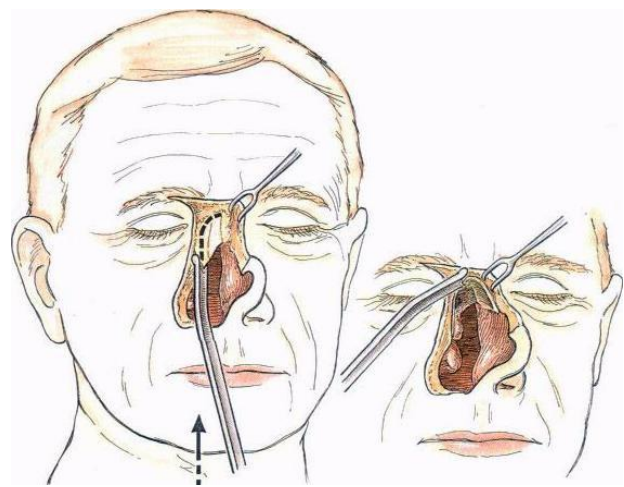


Fig. 6: The classic Transfacial Approach. Curved osteotome used to create bony lateral rhinotomy incision.

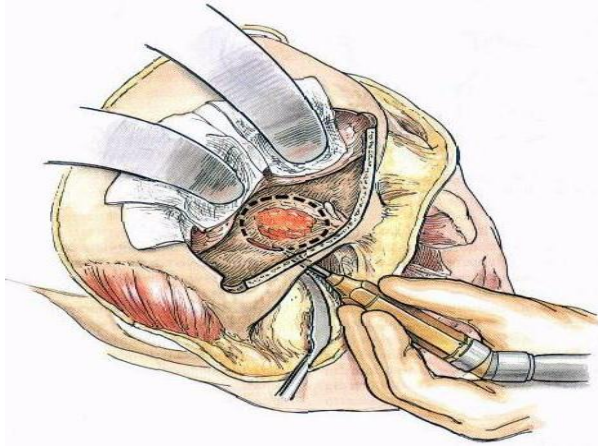


Fig. 7: The neurosurgeon protects the brain from above while the maxillofacial surgeon or head and neck surgeon outlines the amount of bone resection from below.

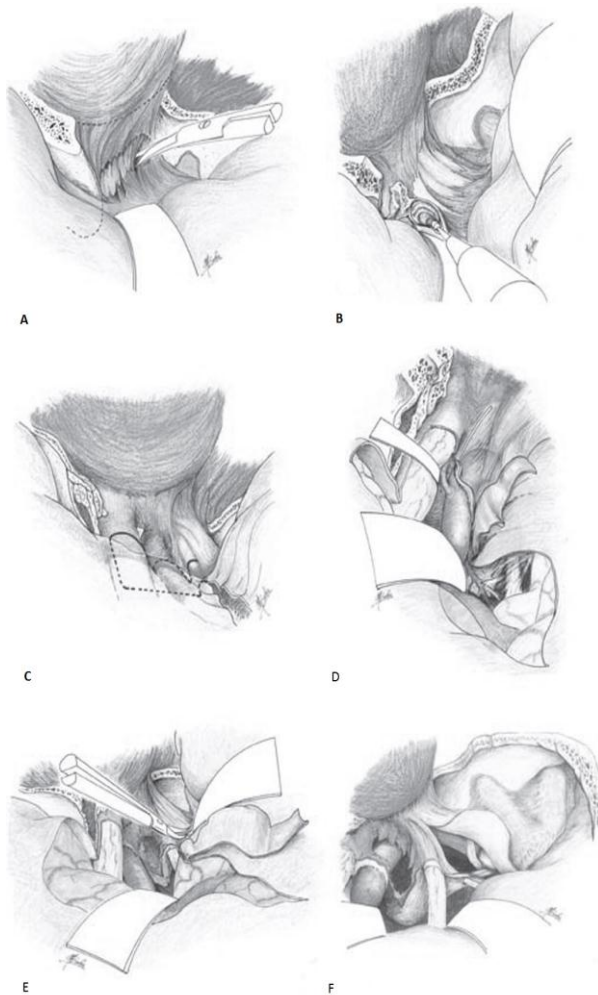


Fig. 8. A, The periosteal reflection, which is continuous with the periorbita, is divided at the superior and inferior margins of the superior orbital fissure. Then the temporal dura propria, forming the superficial layer of the cavernous sinus (CS), can be separated from the content of the superior orbital fissure. B, The cortical bone of the anterior clinoid process and the optic strut are being removed by a

bone curette and a small diamond drill, respectively. C, Dural opening around the paracavernous region. The dotted line shows the dural incision that passes along the sylvian fissure to the superior surface of the optic nerve sheath forward and is then turned laterally at a right angle. D, Dural incision passes backward at a right angle and runs along the medial part of the distal carotid ring and then along the carotid artery. E, Peeling off the temporal dura propria, the dural incision runs along the medial side to the posterior clinoid process and finally along the posterior side of the medial triangle (Hakuba's triangle) to the dural entrance of the oculomotor nerve. F, Finally, the CS is opened so as to expose the internal carotid artery.

DISCUSSION

Advances in treatment of cancer of paranasal sinuses were slow due to a lack of understanding towards lesions of the skull base. Ohngren^[20] (1933) suggested the treatment modality for such cancers as drainage, electrocauterization and radiation therapy. Smith et al^[21] (1954) were the pioneers to describe a combined craniofacial approach for the treatment of 3 patients suffering from advanced fronto-ethmoidal-orbital cancer. This study paved the pathway for further research in this area. In 1959, Malecki^[22] described his technique for combined craniofacial resection including the cribriform area. Ketcham et al^[23] (1963) published a landmark study which established the relative safety and feasibility of combined craniofacial resection. The authors evaluated a cohort of 30 patients affected with advanced paranasal sinus, nasal and orbital cancers. Majority of patients in this study represented failed treatment using other modalities. A total of 19 patients were selected as candidates for craniofacial resection. All patients showed good recovery in the postoperative period, except for one perioperative mortality due to infection. The authors reported further experience with this surgical approach in 1968, exhibiting a cure rate of 30% over a 10-year experience, in a group of patients who were considered unsalvageable.^[24] In 1973, the authors published a study demonstrating an improvement in 5-year survival to 56%.^[25]

With passage of time, new modifications were suggested as Ketcham's work was adopted by more surgical teams. Sisson^[26] (1976) extended Ketcham's approach, using frontal craniotomy and demonstrated methods for skull base reconstruction using bone and cartilage. Schramm^[27] (1979) expanded the role of frontal burr hole and recommended raising of frontotemporal flap for cases with greater involvement of skull base. Clifford^[28] (1980) and Terz^[29] described a combined frontal and temporal approach for removal of lesions from anterior and middle cranial fossae.

The feasibility and safety of craniofacial resection was reported as multiple clinical trials from around the world, both as single institution and multi-institution studies.

Eibling et al^[30] (1993) published a landmark study, whereby they presented a meta-analysis of outcomes of craniofacial resection for anterior skull base malignancy. Their results suggested that high-grade carcinoma involving anterior cranial base is amenable to surgical excision with acceptable disease-free survival in selected patients, at 2 years. More recently (2012), Gil et al^[31] from Memorial Sloan-Kettering Center, presented a study to determine the trends in survival of patients with anterior skull base cancer over several decades and to identify time-related changes in the demographic and clinical characteristics of this population. In all, 282 patients who underwent craniofacial resection at Memorial Sloan-Kettering Cancer Center and Tel Aviv Medical Center were studied. Patients were categorized in accord with the period of surgery: early (1973–1984, n = 34), intermediate (1985–1996, n = 72), and later (1997–2008, n = 176). Patients operated after 1996 had higher rates of comorbidity, dural and pterygopalatine invasion and multicompartamental involvement than those operated before 1996 ($p \leq .001$). There was a significant improvement in 5-year overall and disease-specific survival, from 55% and 57%, respectively, for patients operated before 1996, to 66% and 70%, respectively, for those operated after 1996 ($p = .02$ and $p = .006$, respectively). On multivariate analysis, surgery after 1996 was an independent predictor of outcome (HR, 0.39, $p < .001$). The authors concluded that the survival of patients with anterior skull base cancer is improving.

Mine et al^[32] (2011) presented surgical outcomes of craniofacial resection for sinonasal malignant tumours in 32 patients over a period of 17 years at Chiba University, Japan. The overall survival rate, local control rate and disease-free survival rate, at 5 years, were reported as 72.2%, 74.5%, 85.1% and 66.3% respectively. In a similar study, Cantu et al^[33] presented the results of a mono-institutional series of 366 patients treated with anterior craniofacial resection for malignant paranasal sinus tumors. All tumors were classified according to both the American Joint Committee on Cancer (AJCC)-2002 and the Istituto Nazionale Tumori (INT) classifications. There was intraorbital spread in 108 cases. The skull base was eroded in 127 patients, with dura or brain involvement in 93 patients. The 10-year disease-specific survival was 53.1%. Histologic subtype, INT stage and surgical margins were significant, independent predictors for both local relapse and disease-specific survival (DSS). Similar studies have been published by Bridger,^[34] Cantu,^[35] Ganly,^[36] Gil,^[37,38] Lund,^[39] Maghami,^[40] Nishio,^[41] Palme,^[42] Robbins^[43] and Saito.^[44]

Various multi-institutional studies were also reported as international collaborative studies, such as by Patel et al^[45] (2003) and Ganly et al^[46] (2005). The report by Patel et al^[45] was based on a large cohort that was analyzed retrospectively by an International Collaborative Study Group. 1307 patients who underwent craniofacial resection in 17 institutions were

analyzable for outcome. The median age was 54 years (range, 1–98 years). The majority of tumours (87%) involved the anterior cranial fossa. Squamous cell carcinoma (29%) and adenocarcinoma (16%) were the most common histologic types. With a median follow-up of 25 months, the 5-year overall, disease specific, and recurrence-free survival rates were 54%, 60% and 53%, respectively. The histology of the primary tumour, its intracranial extent and the status of surgical margins were independent predictors of overall, disease-specific and recurrence-free survival on multivariate analysis. The authors concluded that craniofacial resection is a safe and effective treatment option for patients with malignant tumours of the skull base. In the study by Ganly et al,^[46] 1193 patients from 17 institutions were analyzed for postoperative mortality and complications. Postoperative complications were classified into systemic, wound, central nervous system (CNS) and orbit. The authors stated that craniofacial resection is a safe surgical treatment for malignant tumors of the skull base, with an overall mortality of 4.7% and complication rate of 36.3%.

In another publication, Ganly et al^[47] (2005) reported results of an international collaborative study for craniofacial resection of malignant paranasal sinus tumors. A large number of 334 patients from 17 institutions were analyzed for outcome. The median age was 57 years (range, 3–98 years). The most common histologic findings were adenocarcinoma in 107 (32%) and squamous cell carcinoma in 101 (30.2%). The margins of resection were close or microscopically positive in 95 (30%). The 5-year overall, disease-specific, and recurrence free survival rates were 48.3%, 53.3% and 45.8%, respectively. The status of surgical margins, histologic findings of the primary tumour and intracranial extent were independent predictors of overall, disease-specific and recurrence-free survival on multivariate analysis. The authors concluded that craniofacial resection for malignant paranasal sinus tumours is a safe surgical treatment with an overall mortality of 4.5% and complication rate of 33%. Patel et al^[48] (2012) published the findings of an international collaborative study on craniofacial resection (CFR) for esthesioneuroblastoma (ENB). Data on 151 patients who underwent CFR for ENB were collected from 17 institutions that participated in an international collaborative study. Patient, tumor, treatment and outcome data were collected by questionnaires and variables were analyzed for prognostic impact on overall, disease-specific and recurrence-free survival. The majority of tumours were staged Kadish stage C (116 or 77%). Treatment-related complications were reported in 49 (32%) patients. With a median follow-up of 56 months, the 5-year overall, disease-specific and recurrence-free survival rates were 78, 83 and 64%, respectively. Intracranial extension of the disease and positive surgical margins were independent predictors of worse overall, disease-specific and recurrence-free survival on multivariate analysis.

CONCLUSION

The subcranial approach is the procedure of choice for most patients with anterior skull base lesions. The presence of intracranial and extracranial invasion with involvement of the clivus, pterygoid plates, anterior cavernous sinus and sellar region is not a contraindication to this approach.^[44] The use of this procedure or its combination with different approaches depends on the exact location of the lesion.

CONFLICT OF INTERESTS

The author declares that there is no conflict of interests that could influence this work.

FUNDING ACKNOWLEDGEMENTS

The author declares that there was no financial aid obtained from any source for the preparation of this manuscript.

REFERENCES

- Tessier P, Guiot G, Derome P. Orbital hypertelorism: definite treatment of orbital hypertelorism by craniofacial or by extracranial osteotomies *Scandinavian Journal of Plastic and Reconstructive Surgery*, 1973; 7: 39-58.
- Ketchman AS, Wilkins RH, Van Buren JM, Johnson RH, Smith RR. A combined intracranial facial approach to the paranasal sinuses. *Am J Surg*, 1963; 106: 698-703.
- Derome P. Les tumeurs spheno-ethmoidales. *Neurochirurgie*, 1972; 18(Suppl 1): 1-164.
- Derome P. Transbasal approach to tumors invading the skull base. In: Schmidek HH, Sweet WH, eds. *Operative neurosurgical techniques*. 3rd ed. Philadelphia: WB Saunders, 1995; 427-441.
- Benzil DL, Robotti E, Forcht DT, Sullivan P, Bevivino JR, Knuckey NW. Early single-stage repair of complex craniofacial trauma: experimental and clinical study. *Neurosurgery*, 1992; 30: 166-173.
- Cheesman AD, Lund VJ, Howard DJ. Craniofacial resection for tumors of the nasal cavity and paranasal sinuses. *Head and Neck Surgery*, 1986; 8: 429-435.
- Jackson IT, Marsh WR, Hide TA. Treatment of tumors involving the anterior cranial fossa. *Head and Neck Surgery*, 1984; 6: 901-913.
- Raveh J, Vuillemin T. The subcranial-supraorbital and temporal approach for tumors resection. *Journal of Craniofacial Surgery*, 1990; 1: 53-59.
- Sekhar LN, Sen C, Snyderman CH, Janecka IP. Anterior, anterolateral and lateral approaches to extradural petroclival tumors. In: Sekhar LN, Janecka IP, eds. *Surgery of cranial base tumors*. New York: Raven Press, 1993; 157-223.
- Persing JA, Jane JA, Levine PA, Cantrell RW. The versatile frontal sinus approach to the floor of the anterior cranial fossa. *J Neurosurg*, 1990; 72: 513-516.
- Raveh J, Vuillemin T, Sutler F. The subcranial management of combined fronto-basal-midface fractures. *Arch Otolaryngol Head Neck Surg*, 1988; 114: 1114-1122.
- Samii M. Neurosurgical aspects of tumors of the base of the skull. In: Youmans JR, ed. *Neurosurgical surgery*. Philadelphia: WB Saunders, 1990: 3639-3653.
- Sundaresan N, Sachdev V, Krol G. Craniofacial resection for anterior skull base tumors. In: Schmidek HH, Sweet WH, eds. *Operative neurosurgical techniques*. 3rd ed. Philadelphia: WB Saunders, 1995: 415-425.
- Ramina R. The transfrontal basal approach to skull base surgery. Presented at the Sacramento Skull Base Surgery Symposium, Sacramento. California, 1995; 25-30.
- Delfim R, Missori P, Iannetti G, Ciapetta P, Cantore G. Mucoceles of the paranasal sinuses with intracranial and orbital extension: report of 28 cases. *Neurosurgery*, 1993; 32: 901-904.
- Jan M, Dweik A, Destrieux C, Djebbari Y. Fronto-orbital sphenoidal fibrous dysplasia: case report. *Neurosurgery*, 1994; 34: 544-543.
- Morita A, Ebersold MJ, Olsen KD, Foote RL, Lewis JE, Quast LM. Esthesioneuroblastoma: prognosis and management. *Neurosurgery*, 1993; 32: 706-711.
- Donald PJ, editor. *Surgery of the skull base*. Philadelphia: Lippincott-Raven Publishers, 1998; 165-194.
- Meneses MS, Thurel C, Mikol J, et al. Esthesioneuroblastomas with intracranial extension. *Neurosurgery*, 1990; 27: 813-820.
- Ohngren L. Malignant tumors of the maxilloethmoidal region. *Acta Otolaryngol*, 1933; 19: 1-476.
- Smith RR, Klopp CT, Williams MM. Surgical treatment of cancer of the frontal sinus and adjacent areas. *Cancer*. 1954; 7: 991-94.
- Malecki J. New trends in frontal sinus surgery. *Arch Otolaryngol*. 1959; 50: 137-140.
- Ketcham AS, Wilkins RH, Van Buren JM, Smith RR. A combined intracranial facial approach to the paranasal sinuses. *Am J Surg*, 1963; 106: 698-703.
- Van Buren JM, Ommaya AK, Ketcham AS. Ten years' experience with radical combined craniofacial resection of malignant tumors of the paranasal sinuses. *J Neurosurg*, 1968; 28: 341-350.
- Ketcham SA, Chretien PB, Van Buren JM, Hoyer RC, Beazley RM, Herdt JR. The ethmoid sinuses: A re-evaluation of surgical resection. *Am J Surg*, 1973; 126(4): 469-476.
- Sisson GA, Bytell DE, Becker SP. Carcinoma of the paranasal sinuses and craniofacial resection. *J Laryngol Otolaryngol*, 1976; 90: 59-68.
- Schramm VL, Myers EN, Maroon JC. Anterior skull base surgery for benign and malignant disease. *Laryngoscope*, 1979; 89: 1077-91.

28. Clifford P. Transcranial-facial approach for tumors of superior paranasal sinuses and orbit. *J Roy Soc Med*, 1980; 73: 413-19.
29. Terz JJ, Alkane JF, Lawrence W. Craniofacial resection for tumors invading the pterygoid fossa. *Am J Surg*, 1969; 118: 732-40.
30. Eibling DE, Janecka IP, Snyderman CH, Cass SP. Meta-analysis of outcome in anterior skull base resection for squamous cell and undifferentiated carcinoma. *Skull Base Surgery*, 1993; 3(3): 123-129.
31. Gil Z, Fliss DM, Cavel O, Shah JP, Kraus DH. Improvement in survival during the past 4 decades among patients with anterior skull base cancer. *Head Neck*, 2012; 34: 1212-1217.
32. Mine S, Saeki N, Horiguchi K, Hanazawa T, Okamoto Y. Craniofacial resection for sinonasal malignant tumours: Statistical analysis of surgical outcome over 17 years at a single institution. *Skull Base*, 2011; 21: 243-248.
33. Cantu G, Solero CL, Miceli R, Mattana F, Riccio S, Colombo S, Pompilio M, Lombardo G, Formillo P, Quattrone P. Anterior craniofacial resection for malignant paranasal tumors: a monoinstitutional experience of 366 cases. *Head Neck*, 2012; 34: 78-87.
34. Bridger P, Kwok B, Baldwin M, Williams JR, Smee RI. Craniofacial resection for paranasal sinus cancers. *Head Neck*, 2000; 22: 772-780.
35. Cantu G, Solero CL, Mariani L, Salvatori P, Mattavelli F, Pizzi N, Riggio E. Anterior craniofacial resection for malignant ethmoid tumours – a series of 91 patients. *Head Neck*, 1999; 21: 185-191.
36. Ganly I, Patel SG, Singh B, et al. Craniofacial resection for malignant melanoma of the skull base. Report of an international collaborative study. *Arch Otolaryngol Head Neck Surg*, 2006; 132: 73-78.
37. Gil Z, Constantini S, Spektor S, Abergel A, et al. Skull base approaches in the paediatric population. *Head Neck*, 2005; 27: 682-689.
38. Gil Z, Patel SG, Cantu G, Fliss DM, et al. Outcome of craniofacial surgery in children and adolescents with malignant tumors involving the skull base: an international collaborative study. *Head Neck*, 2009; 31: 308-317.
39. Lund VJ, Howard DJ, Wei WI, Cheesman AD. Craniofacial resection for tumors of the nasal cavity and paranasal sinuses — a 17-year experience. *Head Neck*, 1998; 20: 97-105.
40. Maghami E, Talbot S, Patel SG, Singh B, et al. Craniofacial surgery for nonmelanoma skin malignancy: report of an international collaborative study. *Head Neck*, 2007; 29: 1136-1143.
41. Nishio N, Fujimoto Y, Fujii M, Saito K, et al. Craniofacial resection for T4 maxillary sinus carcinoma: managing cases with involvement of the skull base. *Otolaryngol Head Neck Surg*, 2015; 153(2): 231-238.
42. Palme CE, Irish JC, Gullane PJ, Katz MR, et al. Quality of life analysis in patients with anterior skull base neoplasms. *Head Neck*, 2009; 31: 1326-1334.
43. Robbins KT, Ferlito A, Silver CE, Takes RP, et al. Contemporary management of sinonasal cancer. *Head Neck*, 2011; 33: 1352-1365.
44. Saito K, Fukuta K, Takahashi M, Tachibana E, et al. Management of the cavernous sinus in en bloc resections of malignant skull base tumours. *Head Neck*, 1999; 21: 734-742.
45. Patel SG, Singh B, Polluri A, Bridger PG, et al. Craniofacial surgery for malignant skull base tumors. Report of an international collaborative study. *Cancer*, 2003; 98: 1179-87.
46. Ganly I, Patel SG, Singh B, Kraus DH, et al. Complications of craniofacial resection for malignant tumors of the skull base: Report of an international collaborative study. *Head Neck*, 2005; 27: 445-451.
47. Ganly I, Patel SG, Singh B, Kraus DH, et al. Craniofacial resection for malignant paranasal sinus tumors: Report of an international collaborative study. *Head Neck*, 2005; 27: 575-584.
48. Patel SG, Singh B, Stambuk HE, Carlson D, et al. Craniofacial surgery for esthesioneuroblastoma: Report of an international collaborative study. *J Neurol Surg B.*, 2012; 73: 208-220.