

ASSESSMENT OF THE SAFETY VERSUS NEPHROTOXICITY OF USNIC ACID IN RATS: BIOCHEMICAL AND HISTOPATHOLOGICAL STUDIES***Ahlam A. Alahmadi, PhD**

Assistant Professor, Department of Biological Sciences, Faculty of Science, King Abdulaziz University, Jeddah, Saudi Arabia.

***Corresponding Author: Dr. Ahlam A. Alahmadi, PhD**

Assistant Professor, Department of Biological Sciences, Faculty of Science, King Abdulaziz University, Jeddah, Saudi Arabia.

Article Received on 25/09/2017

Article Revised on 16/10/2017

Article Accepted on 06/11/2017

ABSTRACT

Background: Nephrotoxicity is a common sequela of drug administration that has not been well investigated. Usnic acid (UA), a secondary metabolite of certain lichens, was reported to exert hepatotoxic and cardiotoxic effects. **Objectives:** The objective of the present work was to demonstrate the possible nephrotoxic effect of UA (100 and 300 mg/kg). **Methodology:** Thirty adult male rats (150–200 g) were sorted into the following groups: G1 (control rats) received 1% watery carboxymethyl cellulose CMC, G2 received 100 mg UA/kg, and G3 received 300 mg UA/kg; all treatments were administered for 8 weeks using oral gavage. Serum was collected for kidney function measurement, and kidney tissue was removed for ultrastructural studies. **Results:** Usnic acid at a low dose showed slight insignificant effects on both kidney function and ultrastructure. On the other hand, a high dose resulted in the irregularity and thickening of the glomerular membrane and podocyte footlets, and proximal tubules showed loss of microvilli and degenerative changes in basal infolding. Mitochondria showed swelling at a low dose and marked deformity at a high dose. Serum creatinine and blood urea nitrogen (BUN) levels were significantly increased, while there was minor alteration in blood electrolytes. **Conclusion:** UA at a low dose could be considered safe regarding kidney function and structure. If high doses are administered, the kidney function must be monitored or a renoprotective supplement must be combined with UA administration.

KEYWORDS: Kidney, nephrotoxicity, usnic acid, ultrastructure, mitochondria.**ABBREVIATIONS**

UA: Usnic acid; CMC: Carboxymethyl cellulose; Mg: Magnesium; CA: Calcium; ALP: Alkaline phosphatase; ACP: Acid phosphatase; BUN: Blood urea nitrogen; CREA: Creatinine; URCA: Uric acid; ATP: Adenosine triphosphate; TEM: Transmission electron microscopy; PT: Proximal tubules.

INTRODUCTION

Thermogenic agents are well known as "fat burning" because they result in increased energy expenditure.^[1] Usnic acid (UA) is a secondary metabolite of lichen species.^[2,3] Usnic acid was reported to possess a wide range of biological activities, including anti-inflammatory and analgesic effects.^[4] Usnic acid can diffuse through the mitochondrial membranes and promote proton leakage with consequent uncoupling of oxidative phosphorylation.^[5] Oxidative phosphorylation is the process by which ATP is synthesized via specific metabolic pathways involving the oxidation of nutrients.^[6] Terada^[7] reported that the inhibition of uncoupling between electron transport and phosphorylation in mitochondria without affecting the

respiratory chain and ATP synthase can occur using uncouplers of oxidative phosphorylation. Usnic acid was reported to be an uncoupling agent.⁸ Usnic acid is found in many food supplements used for weight reduction.^[3]

Limited studies confined to experimental preclinical pharmacological trials were found to validate the use and safety of UA.^[9-13] Studies regarding the nephrotoxicity of UA are unavailable; thus, the main objective of the present work was to investigate the safety versus nephrotoxicity of different doses of usnic acid in rats using biochemical and ultrastructural studies.

MATERIALS AND METHODS

The experimental work was carried out according to guidelines for animal care approved by the ethical committee at King Fahad Medical Research Center (KFMRC).

Chemicals

(+)-Usnic acid (98%), molecular weight: 344.32, in the form of a yellowish powder was supplied by Sigma-Aldrich (Chemie GmbH, Munich, Germany).

Animals and experimental design

Adult male Sprague-Dawley (SD) rats (n = 30) with an average body weight of 150–200 g were purchased from the Animal House Unit at King Fahad Medical Research Center (KFMRC) and were allowed to acclimatize for one week at 20 °C and humidity (60%) and a dark-light cycle (12/12 h). Animals were randomly sorted into 3 groups (n=10). Group 1 (control) received CMC (vehicle for UA), group 2 received 100 mg UA/kg dissolved in 1% CMC, and group 3 received 300 mg UA/kg in 1% CMC. The dosages of UA were selected based on previous studies.^[9,14] All doses were given orally for 5 days/week for 8 weeks, and the body weights were recorded once weekly. The percentage change in the body weight was calculated as follows: final weight – initial weight divided by initial weight × 100.

Animal sacrifice and blood and kidney collection

At the end of the experiment, blood was collected from ether anesthetized animals after overnight fasting between 7:00 and 9:00 am via orbital puncture,^[15] centrifuged and stored at –70 °C for further evaluation of kidney function. After blood collection, the rats were euthanized by decapitation. The abdomen and thoracic were opened. The heart was perfused with normal saline followed by 2.5% glutaraldehyde in phosphate buffer, pH 7.4, to ensure fixation in situ. The kidneys were dissected and weighed to determine the kidney index = (kidney weight/body weight) x100. Small pieces (1 mm³) were cut from the cortex and re-fixed in same fixative for further transmission electron microscopy processing in electron microscopy unit in KFMRC. Toluidine blue-stained sections (one micron thick) were examined for orientation, and then ultrathin sections were prepared, followed by staining with uranyl acetate and lead citrate according to Ross et al.^[16] Examination was performed using Philip CM 100 electron microscopy (Netherlands).

The rats were sacrificed by cervical dislocation under deep ether anesthesia. The abdomen and thoracic were opened. kidney were extracted and weighed immediately

Statistical Analysis

The Statistical Package for Social Science (SPSS 22 for Windows) program was used for data analysis. The numerical data are presented as the means ± standard error (SE). One-way analysis of variance (ANOVA) and Student's *t*-test were used for the comparison of variables between groups. Statistically significant results were considered at a P-value < 0.05.

RESULTS

Body weight and kidney index

Regarding significant changes in body weight, body weight gain was observed between the control and usnic acid-treated groups. On the other hand, UA at a high dose (G3) resulted in a significant increase in the kidney index compared with that of the control (G1) and low-dose (G2) groups (P = 0.003 and P = 0.003), as in Table 1.

Biochemical results

Table 2 shows the effect of different doses of UA on some kidney function parameters. UA at a low dose (100 mg/kg) significantly increased the serum albumin and creatinine. At a high dose (300 mg/kg), UA significantly increased Mg, Ca, BUN, and creatinine. Acid phosphatase was found to be significantly decreased in both doses. On the other hand, an insignificant decrease in alkaline phosphatase was found.

Ultrastructure study

In the present study, both semi-thin and ultrastructure photographs provided precise demonstration of cellular changes in the kidney parenchyma induced by the administration of usnic acid. Semi-thin sections of G1 control kidney cortex showed normal glomerular capillaries. Nearby proximal tubules were lined by cells with an intact brush border in contact with narrow lumina. Peritubular capillaries were normal and not dilated (Figure 1A). By TEM glomerular capillary showed normal fenestrated endothelium and normal thickness basement membrane in contact with podocytes with regular normal footlets (Figure 1B).

Usnic acid given at a dose of 100 mg/kg (G2) results in a slight enlargement and congestion of renal glomeruli and basement membrane thickening. Proximal tubules showed no changes except tiny basal vacuolation. Peritubular capillaries were dilated and congested (Figure 1C). TEM showed clearly such changes. Podocytes related to congested capillaries exhibited electron-dense cytoplasm with increased nuclear heterochromatin. Slight thickening of the glomerular membrane was observed (Figure 1D).

In G3 (300 mg/kg UA), slight shrunken glomeruli with protein deposit within the Bowman capsule were demonstrated. Proximal tubules showed basal degeneration and desquamated cells into the lumen (Figure 1E). Destructed endothelial lining and changes in podocyte cytoplasm and the fusion of thickened footlets could be seen in EM photographs (Figure 1F).

Regarding changes in proximal tubules, Figure 2 demonstrated both semi- and ultrathin sections taken for control and experimental groups. In G1 control rats, proximal tubules in semi-thin sections showed normal high cuboidal cells with an intact brush border. Peritubular capillaries were normal and not dilated (Figure 2A). By EM, proximal tubule cells showed large euchromatic nuclei, a normal brush border, basal infoldings, basement membrane and a normal mitochondrial population (Figure 2B).

The administration of low-dose UA (100 mg) resulted in slight changes in proximal tubules. Peritubular capillaries were dilated and congested (Figure 2C). By EM, the tubules showed a normal brush border, tiny basal vacuoles and normal crowded mitochondria (Figure 2D).

Semi-thin sections of G3 (300 mg/kg) showed shrunken tubules with basal degeneration and numerous vacuoles and desquamated cells. Peritubular capillaries were dilated and congested (Figure 2E). EM photographs taken for those tubules showed marked degeneration of basal infoldings, mitochondria and electron lucent irregular spaces with degenerated cells in the lumen (Figure 2F).

Because UA primarily works via the uncoupling of oxidative phosphorylation at the mitochondrial level, in the present study, a high dose resulted in the alteration of mitochondria morphology in proximal tubule cells. In most samples, swollen mitochondria rarified matrixes and damaged cristae were seen. Severely affected animals showed marked deformity of the mitochondria (bell dump shape) with a dark matrix and vesicular cristae. The PT cytoplasm in those samples showed loss of normal basal infoldings (Figure 3).

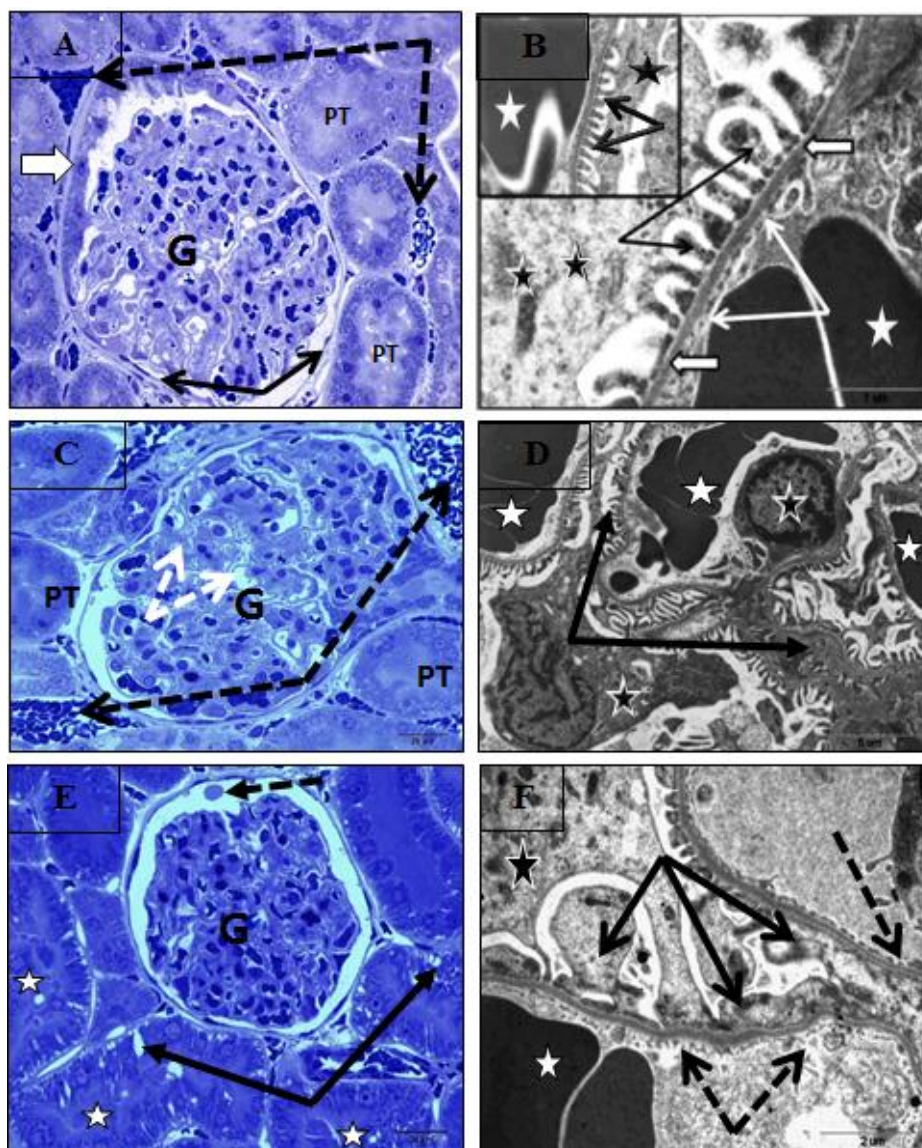


Figure 1

Figure (1): **A:** semithin section of renal corpuscle from G1 shows normal glomerular capillaries (G). Proximal tubules (PT) lined by cells with intact brush border. Peritubular capillaries appear not dilated (dotted arrows) (Toluidine blueX1000). **B:** Ultrathin section of G1 shows part of glomerular capillary contain erythrocytes (white star), intact fenestrated endothelium (thin white arrows) and regular basement membrane (thick white arrows) in contact with intact podocyte (black star) footlets (thin black arrows) (TEM X 4800). **C:** semithin section of renal corpuscle from G2 received 100 mg UA shows slight enlarged glomerulus (G) with slight congested capillaries and basement membrane thickening (dotted white arrows). Proximal tubules (PT) appear intact. Peritubular capillaries are dilated and congested (black dotted arrows) (Toluidine blueX1000). **D:** Ultrathin section of G2 received 100 mg UA showing congested glomerular capillaries (white stars), podocytes with electron dense cytoplasm (black stars) and increased nuclear heterochromatin. Slight thickening of glomerular membrane (black arrows) is observed (TEM X 5400). **E:** Semithin

section of renal corpuscle from G3 received 300 mg UA shows slight shrunken glomerulus (G) protein deposit within capsule (dotted arrows). Proximal tubules (PT) show basal degeneration (black arrows) and desquamated cells into the lumen (stars) (Toluidine blueX1000). **F:** Ultrathin section of G3 received 300 mg UA showing destructed endothelial lining (dotted arrows), dense granules in podocyte cytoplasm (black stars) with fused thickened footlets (black arrows) (TEM X 10000).

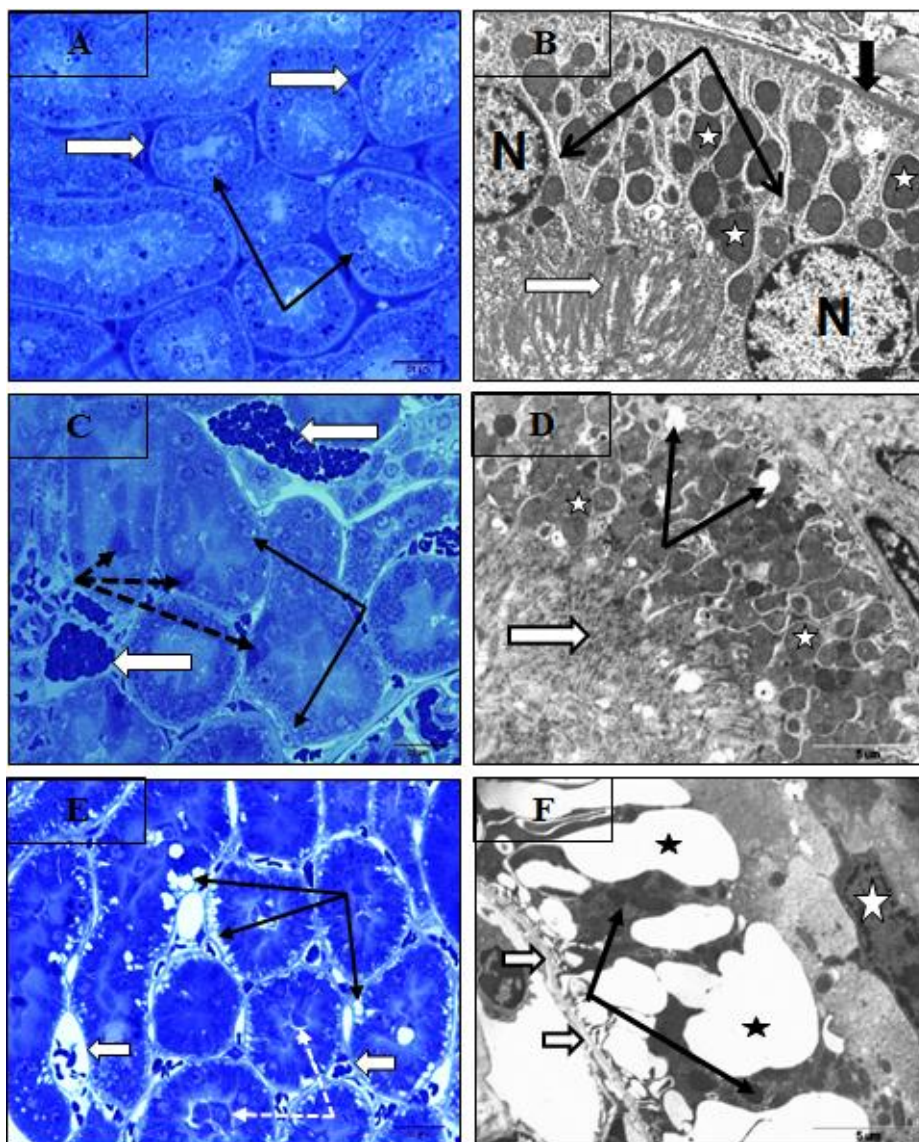


Figure 2

Figure 2: A: Semithin section of G1 showing normal proximal tubule (black arrows) and thin Peritubular capillaries (white arrows) (Toluidine blueX1000). **B:** Ultrathin section of G1 showing part of proximal tubules showing large euchromatic nucleus (N), normal brush boarder (white arrow), normal based infoldings (thin black arrows), and mitochondria (white star). Normal basement membrane thickness (thick black arrow) (TEM X 3600). **C:** semithin section of renal corpuscle from G2 received 100 mg UA showing tiny vacuoles in basal parts of PT (thin arrows). Few dark degenerated cells (dotted arrows). Notice: marked peritubular capillaries (white arrows) (Toluidine blueX1000). **D:** Ultrathin section of G2 received 100 mg UA showing basal tiny vacuoles (black arrows), intact crowded mitochondria (stars), intact brush boarder (white arrow) (TEM X 3000). **E:** semithin section of renal corpuscle from G3 received 300 mg UA showing shrunken tubules with numerous basal vacuoles (black arrows), desquamated cells (dotted white arrows), and dilated capillaries (white arrows) (Toluidine blueX1000). **F:** Ultrathin section of G3 received 300 mg UA shows basal part of proximal tubules showing marked degeneration of basal infoldings, mitochondria and electron dense irregular spaces (stars) and Degenerated cell in the lumen (white star) (TEM X 36000).

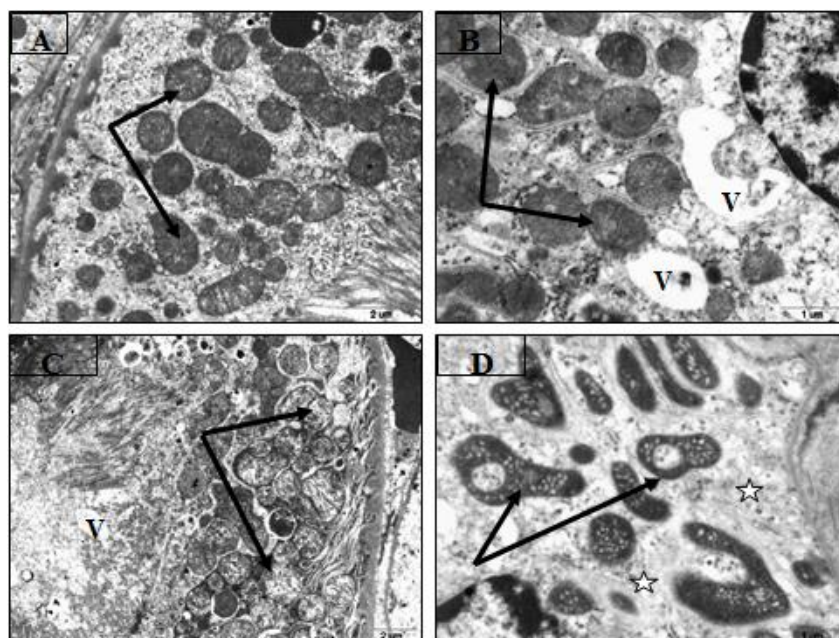


Figure 3

Figure (3): Ultrathin sections of mitochondria in proximal tubules of: **A:** G1 showing normal mitochondria with intact cristae (arrows) (TEM X 9000). **B:** G2 received 100 mg UA show vacuolation (V) with slight changes in mitochondria (arrows) (TEM X 14000). **C:** G3 received 300 mg UA showing swollen mitochondria, rarified matrix and damaged cristae (arrows) (TEM X 9000). **D:** G3 showing severely affected proximal tubule with marked deformity of mitochondria (bell dump shape) having dark matrix and vesicular cristae (arrows). The cytoplasm showed loss of normal basal enfoldings (stars) (TEM X 14000).

Table 1: Body weight, body weight gain (%), and kidney index of control and UA-treated groups.

Parameter		Control (G1)	100 mg UA/kg (G2)	300 mg UA/kg (G3)
Body weight (g)	At the start	195.18±3.06	199.55±5.34	198.27±6.15
	At the end	331.15±4.65	329.41±13.62	322.97±7.67
Body weight gain (%)		70.25±4.50	65.17±5.58	60.98±2.84
Kidney index		0.3440±0.00674	0.3435±0.00707	0.3769±0.00707 ^{a, b}

The data are expressed as the means ± SE. (a): significance versus G1; (b): significance versus G2.

Percentage change in the body weight was calculated as final weight – initial weight divided by initial weight × 100.

Table 2: Effect of usnic acid (UA) administration (100 or 300 mg/kg) on kidney function parameters.

Parameters	Group (1) (1% CMC)	Group (2) (100 mg UA/kg)	Group (3) (300 mg UA/kg)
Mg (mmol/L)	1.01±0.04	1.07±0.04	1.34±0.05 ^{a, b}
CA (i/L)	2.605±0.04	2.689±0.02	2.828±0.08 ^a
ALP (i/L)	125.7±7.03	115.10±5.04	117.0±11.16
ACP (i/L)	3.922±0.19	3.305±1.05 ^a	2.871±0.35 ^a
BUN (i/L)	6.35±0.99	7.93±0.83	12.06±0.62 ^a
CREA (i/L)	31±1.48	47±2.52 ^a	65±4.42 ^a
URCA (i/L)	77.1±8.11	85.1±11.88	70.125±8.24

Data were expressed as the means ± SE. (a) Significance versus group (1); (b) significance versus group (2).

Mg: Magnesium; CA; Calcium; ALP: Alkaline phosphatase; ACP: Acid phosphatase; BUN: Blood urea nitrogen; CREA: Creatinine; URCA: Uric acid.

DISCUSSION

It is well known that the kidney is the site where most drugs and their metabolites are eliminated with subsequent drug-induced renal injury.^[17] Usnic acid is known as a thermogenic agent with numerous biological effects.^[18,19] It was used in several lipolytic preparations

to control body weight gain and treat obesity.^[20] In the present study, UA at both concentrations did not produce any significant changes in the body weight of lean rats. Data regarding the effect of UA on lean body weight are lacking, and most studies have concentrated on its effect as a thermogenic agent in obese individuals.^[21]

UA toxicity was reported in both human and experimental animal liver. Acute liver failure was reported in human intoxication upon the administration of usnic acid or food supplements containing UA.^[21-25] Literature regarding the association between nephrotoxicity and UA is unavailable. In the present study, UA at a higher concentration (300 mg/kg) was found to significantly increase the kidney index. Increased kidney weight due to inflammatory reactions was described with nephrotoxic drug-induced lesions.^[26] The increase in the kidney index observed herein could be related to peritubular capillary dilation and congestion observed in semi-thin sections of those samples. A similar observation was reported in renal disorders associated with many drug and herbal toxic changes.^[27]

Biochemical analysis of kidney functions showed that UA at a low dose (100 mg/kg) significantly increased serum albumin and creatinine. Blood urea nitrogen (BUN) and creatinine were also significantly increased in the high-dose group. Acid phosphatase was found to be significantly decreased at both doses. An insignificant decrease in alkaline phosphatase was found. Estimation of the serum creatinine and BUN levels was used in studies to evaluate the functional and structural integrity of kidney glomerular and tubular components.^[28,29] Kore et al.^[30] and Babu et al.^[31] reported that the creatinine and BUN serum levels could be used as reliable indicators to evaluate renal function. Its increase in serum could be either related to a decreased glomerular filtration rate^[32] or damaged renal tubules.^[33] Both structural alterations were observed at the level of the ultrastructure of the present samples. Acid phosphatase is a lysosomal enzyme that hydrolyses organic phosphates at an acidic pH. It was reported to be in the proximal tubule basal infolding, glomerular capillary basal lamina, podocyte membrane and endothelial basement membrane, where it was suggested to play a role in facilitating ultrafiltration and the clearance of macromolecular debris.^[34] Thus, one can conclude that the damage of those membranes by UA could underline the increase in acid phosphatase observed in the present study. However, other sources of this enzymes could have an impact.

In the present study, UA at a high dose (300 mg /kg) resulted in a significant increase in Mg and Ca, and the mitochondrial calcium content was reported to be linked to oxidative phosphorylation. Nylen and Wrogemann^[35] and Glesby et al.^[36] reported that muscle necrosis in dystrophic mice was linked to the accumulation of calcium within mitochondria and increased serum calcium. Thus, the increase in calcium could, in the present study, have a similar role in the tubular epithelial damage observed herein.

Recent work has shown that UA results in ATP depletion that was suggested to alter the homeostasis of calcium with subsequent cellular damage.^[37] The magnesium ion Mg^{2+} acts as a cofactor for ATP, which is essential for

cell life, and it was also reported to play a role as a second messenger.^[38] Variations in external Mg^{2+} can modulate the activity of ATP synthase and control the rate of oxidative phosphorylation.^[39] The increase in Mg concentration in the present study was most likely linked to the increase in Ca and inhibition of ATP synthesis by UA.^[40] This suggestion must be confirmed by further studies. Biochemical kidney function alterations were previously reported in cases of chemical- and drug-induced nephrotoxicity; the mechanism was suggested to be due to both glomerular and tubular damage.^[41]

Proximal tubule epithelial damage with alteration of mitochondrial organelles and increase in dense bodies are the main ultrastructural changes observed in the high-dose group.^[42,43] The uncoupling of oxidative phosphorylation by UA was known to occur via the inhibition of mitochondrial function.^[18] UA toxicity of cardiac fibroblasts was attributed to be related to mitochondrial imbalance.^[12,44]

Uronic acid at a dose of 50 or 200 mg/kg for 5 days was reported by Pramyothin et al.^[45] to result in mitochondrial swelling in rat hepatocytes. A similar finding was observed by Al-Ahmadi et al.^[9] in rat hepatocytes. The increase in dense bodies was described to be associated with degenerative changes in kidney tubular cells.^[46] Based on both present biochemical and ultrastructural recorded data, the present study could be preliminary, and the nephrotoxic effect encountered at a high dose could be attributed to the low solubility of UA in water^[47] with possible accumulation in proximal renal tubules and subsequent damage of cellular organelles, namely, mitochondria. Further work is needed to study the exact mechanism underlying the nephrotoxic effect of UA.

In conclusion, both biochemical and ultrastructural studies performed in the present study pointed to the safety of UA regarding kidney function and structure when administered at low doses. Chronic use of UA at high doses exerts a nephrotoxic effect. Monitoring kidney function must be performed in those administered supplements containing UA, and an alternative use of renoprotective agents could be advised.

ACKNOWLEDGEMENTS

The author acknowledges Professor Soad Shaker Ali, Anatomy Department, King Abdulaziz University, Jeddah, Saudi Arabia, for reviewing the ultrastructural part of this work.

FUNDING

Research received no specific grant from any funding agency in the public, commercial, private, or not-for-profit sectors

DECLARATION OF CONFLICTING INTEREST

The Author declares that there is/are not conflict(s) of interest.

REFERENCES

- Vaughan RA, White AC, Beam JR, et al. Effect of novel dietary supplement on metabolism *in vitro* and *in vivo*. *J Tradit Complement Med*, 2017; 7(1): 1-8.
- Ingolfsson K. Usnic acid. *Phytochemistry*, 2002; 61(7): 729-36.
- Cocchietto M, Skert N, Nimis PL, Sava G. A review on usnic acid, an interesting natural compound. *Naturwissenschaften*, 2002; 89(4): 137-46.
- Molnar K, Farkas E. Current results on biological activities of lichen secondary metabolites: a review. *Z Naturforsch C.*, 2010; 65(3-4): 157-73.
- Joseph A, Lee T, Moland CL, et al. Effect of (+)-usnic acid on mitochondrial functions as measured by mitochondria-specific oligonucleotide microarray in liver of B6C3F1 mice. *Mitochondrion*, 2009; 9(2): 149-58.
- Papa S, Martino PL, Capitanio G, et al. The oxidative phosphorylation system in mammalian mitochondria. *Adv Exp Med Biol*, 2012; 942: 3-37.
- Terada H. Uncouplers of oxidative phosphorylation. *Environ Health Perspect*, 1990; 87: 213-8.
- Abo-Khatwa AN, Al-Robai AA, Al-Jawhari DA. The uncoupling of oxidative phosphorylation of mouse liver mitochondria *in vivo* by usnic acid. *J KAU Sci*, 2005; 17(1): 35-45.
- Al-Ahmadi AA, Ayuob NN, Ali SS, Al-Robai AA, Abo-Khatwa NA. Effect of (+)-usnic acid as a fat burner on the rat hepatocyte; Correlated histological and biochemical *in vivo* study. *J Anim Vet Adv*, 2012; 11(9): 1368-77.
- Behera BC, Mahadik N, Morey M. Antioxidative and cardiovascular-protective activities of metabolite usnic acid and psoromic acid produced by lichen species *Usnea complanata* under submerged fermentation. *Pharm Biol*, 2012; 50(8): 968-79.
- Liu Q, Zhao X, Lu X, Fan X, Wang Y. Proteomic study on usnic-acid-induced hepatotoxicity in rats. *J Agric Food Chem*, 2012; 60(29): 7312-7.
- Yokouchi Y, Imaoka M, Niino N, Kiyosawa N, Sayama A, Jindo T. (+)-Usnic acid-induced myocardial toxicity in rats. *Toxicol Pathol*, 2015; 43(3): 424-34.
- Garcia-Cortes M, Robles-Diaz M, Ortega-Alonso A, Medina-Caliz I, Andrade RJ. Hepatotoxicity by dietary supplements: a tabular listing and clinical characteristics. *Int J Mol Sci*, 2016; 17(4): 537.
- Al-Bekairi AM, Qureshi S, Chaudhry MA, Krishna DR, Shah AH. Mitodepressive, clastogenic and biochemical effects of (+)-usnic acid in mice. *J Ethnopharmacol*, 1991; 33(3): 217-20.
- Waynforth HB. *Experimental and Surgical Technique in the Rat*. New York, NY: Academic Press, 1980.
- Ross MH, Kaye GI, Pawlina W. *Histology: A Text and Atlas*. 4th Ed. Philadelphia: Lippincott Williams & Wilkins, 2003.
- Decloedt E, Maartens G. Drug-induced renal injury. *CME*, 2011; 29(6): 252-5.
- Han D, Matsumaru K, Rettori D, Kaplowitz N. Usnic acid-induced necrosis of cultured mouse hepatocytes: inhibition of mitochondrial function and oxidative stress. *Biochem Pharmacol*, 2004; 67(3): 439-51.
- Araujo AA, de Melo MG, Rabelo TK, et al. Review of the biological properties and toxicity of usnic acid. *Nat Prod Res*, 2015; 29(23): 2167-80.
- Gunawan B, Kaplowitz N. Clinical perspectives on xenobiotic-induced hepatotoxicity. *Drug Metab Rev*, 2004; 36(2): 301-12.
- Durazo FA, Lassman C, Han SH, et al. Fulminant liver failure due to usnic acid for weight loss. *Am J Gastroenterol*, 2004; 99(5): 950-2.
- Favreau JT, Ryu ML, Braunstein G, et al. Severe hepatotoxicity associated with the dietary supplement LipoKinetix. *Ann Intern Med*, 2002; 136(8): 590-5.
- Neff GW, Reddy KR, Durazo FA, Meyer D, Marrero R, Kaplowitz N. Severe hepatotoxicity associated with the use of weight loss diet supplements containing ma huang or usnic acid. *J Hepatol*, 2004; 41(6): 1062-4.
- Lu X, Zhao Q, Tian Y, Xiao S, Jin T, Fan X. A metabonomic characterization of (+)-usnic acid-induced liver injury by gas chromatography-mass spectrometry-based metabolic profiling of the plasma and liver in rat. *Int J Toxicol*, 2011; 30(5): 478-91.
- Yellapu RK, Mittal V, Grewal P, Fiel M, Schiano T. Acute liver failure caused by 'fat burners' and dietary supplements: a case report and literature review. *Can J Gastroenterol*, 2011; 25(3): 157-60.
- Natochin YV, Bakhteeva VT, Karpenko LA. Renal failure and nephrotoxic drug-induced disturbances in rat kidney tissue. *Ren Fail*, 1994; 16(6): 687-96.
- Basir A, Khan A, Mustafa R, et al. Toxicopathological effects of lambda-cyhalothrin in female rabbits (*Oryctolagus cuniculus*). *Hum Exp Toxicol*, 2011; 30(7): 591-602.
- Naughton CA. Drug-induced nephrotoxicity. *Am Fam Physician*, 2008; 78(6): 743-50.
- Shahrbaf FG, Assadi F. Drug-induced renal disorders. *J Renal Inj Prev*, 2015; 4(3): 57-60.
- Kore KJ, Shete RV, Kale BN, Borade AS. Protective role of hydroalcoholic extract of *Ficus carica* in gentamicin induced nephrotoxicity in rats. *Int J Pharm Life Sci*, 2011; 2(8): 978-82.
- Babu SV, Urolagin DK, Veeresh B, Attanshetty N. *Anogeissus latifolia* prevents gentamicin induced nephrotoxicity in rats. *Int J Pharm Life Sci*, 2011; 3(1): 1091-5.
- Samra M, Abcar AC. False Estimates of elevated creatinine. *Perm J.*, 2012; 16(2): 51-2.

33. Alarifi S, Al-Doaiss A, Alkahtani S, et al. Blood chemical changes and renal histological alterations induced by gentamicin in rats. *Saudi J Biol Sci*, 2012; 19(1): 103-10.
34. Rudiger J, Kalicharan D, Halbhuber KJ, van der Want JJ. Extralysosomal localisation of acid phosphatase in the rat kidney. *Histochem Cell Biol*, 1998; 109(4): 375-82.
35. Nylen EG, Wrogemann K. Mitochondrial calcium content and oxidative phosphorylation in heart and skeletal muscle of dystrophic mice. *Exp Neurol*, 1983; 80(1): 69-80.
36. Glesby MJ, Rosenmann E, Nylen EG, Wrogemann K. Serum CK, calcium, magnesium, and oxidative phosphorylation in mdx mouse muscular dystrophy. *Muscle Nerve*, 1988; 11(8): 852-6.
37. Chen S, Zhang Z, Wu Y, et al. Endoplasmic reticulum stress and store-operated calcium entry contribute to usnic acid-induced toxicity in hepatic cells. *Toxicol Sci*, 2015; 146(1): 116-26.
38. Li FY, Chaigne-Delalande B, Kanellopoulou C, et al. Second messenger role for Mg²⁺ revealed by human T-cell immunodeficiency. *Nature*, 2011; 475(7357): 471-6.
39. Rodriguez-Zavala JS, Moreno-Sanchez R. Modulation of oxidative phosphorylation by Mg²⁺ in rat heart mitochondria. *J Biol Chem*, 1998; 273(14): 7850-5.
40. Igamberdiev AU, Kleczkowski LA. Optimization of ATP synthase function in mitochondria and chloroplasts via the adenylate kinase equilibrium. *Front Plant Sci*, 2015; 6: 10.
41. Kim SY, Moon A. Drug-induced nephrotoxicity and its biomarkers. *Biomol Ther*, 2012; 20(3): 268-72.
42. Ribeiro-Costa RM, Alves AJ, Santos NP, et al. *In vitro* and *in vivo* properties of usnic acid encapsulated into PLGA-microspheres. *J Microencapsul*, 2004; 21(4): 371-84.
43. Santos NPDS, Nascimento SC, Wanderley MS, et al. Nanoencapsulation of usnic acid: an attempt to improve antitumour activity and reduce hepatotoxicity. *Eur J Pharm Biopharm*, 2006; 64(2): 154-60.
44. Cheng YB, Wei LL, Gu N, et al. Oral acute toxicity of (+)-usnic acid in mice and its cytotoxicity in rat cardiac fibroblasts. *Nan Fang Yi Ke Da Xue Xue Bao*, 2009; 29(8): 1749-51.
45. Pramyothin P, Janthasoot W, Pongnimitprasert N, Phrukudom S, Ruangrunsi N. Hepatotoxic effect of (+) usnic acid from *Usnea siamensis* Wainio in rats, isolated rat hepatocytes and isolated rat liver mitochondria. *J Ethnopharmacol*, 2004; 90: 381-7.
46. Rabah SO. Acute taxol nephrotoxicity: histological and ultrastructural studies of mice kidney parenchyma. *Saudi J Biol Sci*, 2010; 17(2): 105-14.
47. Francolini I, Taresco V, Crisante F, Martinelli A, D'Ilario L, Piozzi A. Water soluble usnic acid-polyacrylamide complexes with enhanced antimicrobial activity against *Staphylococcus epidermidis*. *Int J Mol Sci*, 2013; 14(4): 7356-69.