

**ONE MORE CUTANEOUS DIRT LIKE ADHERENT DISEASE: MILIARIA RUBRA  
WITH EXFOLIATION****Jayakar Thomas\* and Deepthi Ravi**

Department of Dermatology, Sree Balaji Medical College &amp; Hospital, Chromepet, Chennai, India.

**\*Corresponding Author: Jayakar Thomas**

Department of Dermatology, Sree Balaji Medical College &amp; Hospital, Chromepet, Chennai, India.

Article Received on 27/09/2017

Article Revised on 18/10/2017

Article Accepted on 08/11/2017

Cutaneous dirt adherent disease (CDAD) is a broad term devised by Chinese dermatologists to indicate a group of disorders having dirt like appearance which may be due to keratotic or pigmented lesions. The conditions which have been included under CDAD till now include Dermatitis neglecta, Terra firma-forme dermatosis, Malassezia dermatosis, atopic dermatitis with post inflammatory hyperpigmentation, X-linked ichthyosis, confluent and reticulated papillomatosis and acanthosis nigricans.<sup>[1]</sup> Here we are including one more condition under CDAD i.e. Miliaria rubra with exfoliation.

Dermatitis neglecta is the most common of the above conditions and is caused by not cleaning the skin for a long period of time and they lesions resolve on cleaning with soap.<sup>[2]</sup> In Terra firma-forme dermatosis, the patients have a history of cleaning the skin.

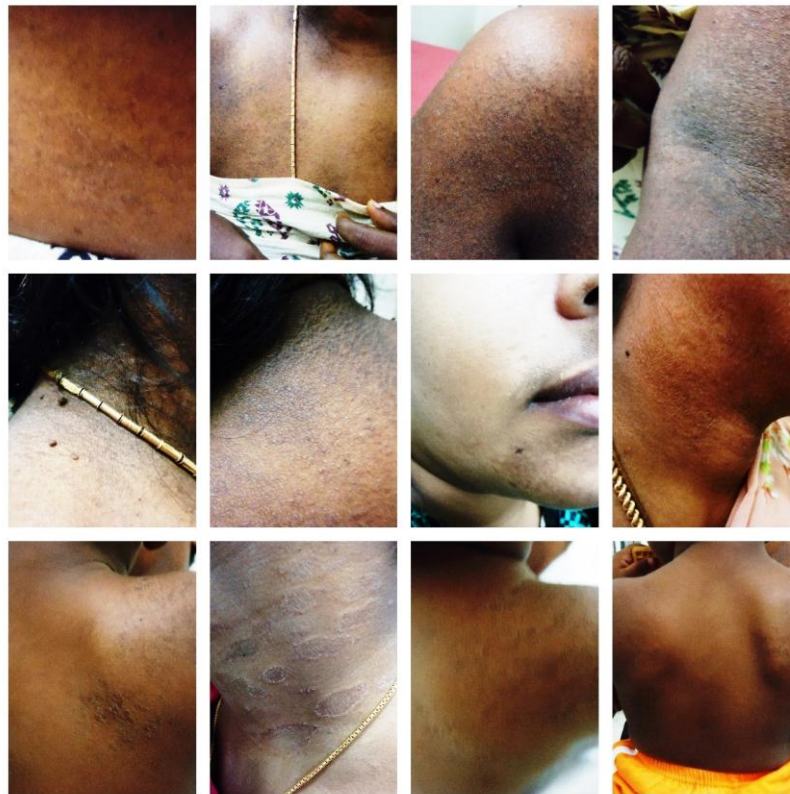
It does not respond to cleansing with soap but resolves on cleaning with alcohol swabs.<sup>[3-4]</sup> The other causes of CDAD do not respond to cleaning with soap or alcohol swabbing. If a 10% KOH examination shows a spaghetti and meat ball appearance with yeast cells and pseudomycelial hyphae, it is suggestive of Malassezia dermatosis. Some patients also respond to paroxetine indicating the role of psychological factors in CDAD.<sup>[5]</sup>

If the IgE level is elevated, family history of atopy is present and if there is more of flexural involvement, it is suggestive of atopic dermatitis with post inflammatory hyperpigmentation. If the legs are mainly involved, winter aggravation and there are centrally adherent and peripherally free scales, it is suggestive of X-linked ichthyosis. Confluent and reticulated papillomatosis (CARP) affects the central trunk such as the interscapular and the inframammary areas and the lesions are verrucous, reticular and erythematous. In acanthosis nigricans symmetrical velvety lesions are seen over the intertriginous areas. It may be associated with endocrinologic abnormalities such as insulin resistance and poly cystic ovarian disease.

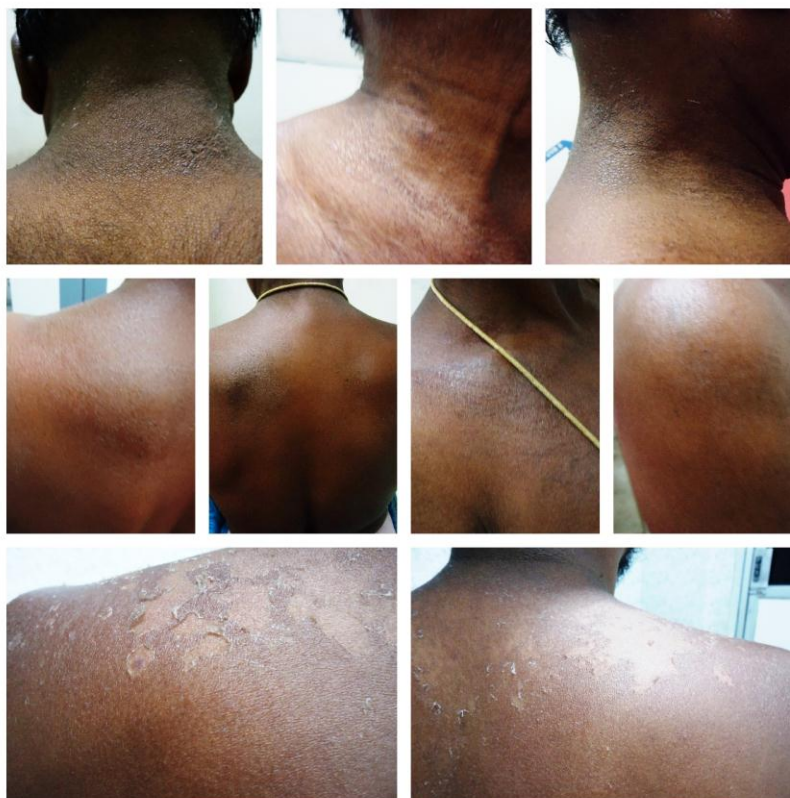
Miliaria results from obstruction of the sweat ducts and is commonly seen in hot and humid climates. Depending on the level of obstruction, miliaria is classified into four types namely miliaria crystallina (obstruction in the superficial parts of the epidermis, miliaria rubra (deeper in the epidermis), miliaria profunda (dermis) and miliaria pustulosa (when pustules are seen due to inflammation

and secondary infection). The management is to avoid further sweating, by keeping the patient in a cool environment, soothing emollients. Topical steroids and oral antibiotics may also be needed in severe cases and those associated with inflammation and secondary infection. Miliaria rubra resolves with exfoliation and gives the appearance of CDAD

Here we present a series of 7 patients who had had miliaria rubra and presented with resolving lesions with exfoliation (Figure 1 and 2). There were three male and four female patients. There were no active lesions of miliaria rubra in any of these patients. This condition could have been mistaken for any other CDAD. Thus miliaria rubra with exfoliation could be considered as one more cutaneous dirt like adherent disease and thus should be considered as one of the differentials if a patient presents with dirt like lesions over the skin.



**Figure 1: Four patients showing Miliaria rubra with exfoliation. Note the dirt like appearance of the skin.**



**Figure 2: Three patients showing Miliaria rubra with exfoliation. Note that there are no active lesions. Note the exfoliation having the appearance of dirt like lesions.**

**REFERENCES**

1. Tan C; Dirt-Adherent dermatosis: Not worth an additional name. *Arch dermatol*, 2010; 146(6): 679-680.
2. Douri T. Neglecta Dermatitis: Four Cases Series. *J Turk Acad Dermatol*, 2015; 9 (4): 1-5.
3. Moon J, Kim MW, Yoon HS *et al.* A Case of Terra Firma-Forme Dermatitis: Differentiation from other Dirty-Appearing Diseases. *Ann Dermatol*, 2016; 28(3): 413-415.
4. Greywal T, Cohen PR. Terra firma-forme dermatosis: A report of ten individuals with Duncan's dirty dermatosis and literature review. *Dermatol Pract Concept*, 2015; 5(3): 29-33.
5. Shan SJ, Xu TH, Liu J *et al.* Cutaneous dirt-adherent disease with single apparent transverse leukonychia on the fingernails. *Arch dermatol*, 2009; 145(9): 1070-1071.