

EVALUATION OF X-RAY FINDINGS ALONG WITH MAGNETIC RESONANCE IMAGING (MRI) IN THE CONCEPT OF POTT'S SPINE PATIENTS**Anil Yadav^{1*}, Dr. Nouratan Singh¹, Dr. A. K. Gupta², Dr. Ramakant Yadav³ and Dr. Kailash Mittal⁴**

^{1*}Ph.D. Scholar, Radiographer (MRI/CT SCAN) & Guest Faculty (Deptt. of Radiological & Imaging Technology) Paramedical College, Saifai, Etawah (U.P.), India.

^{1*}Department of Radiology, U.P. University of Medical Sciences, Saifai, Etawah (U.P.), India.

¹Department of Pathology & Blood Bank, U.P. University of Medical Sciences, Saifai, Etawah (U.P.)

²Head of Department of Radiology, F.H. Medical College, Tundla (U.P.),

²Ex. H.O.D. Department of Radiology, U.P. University of Medical Sciences, Saifai, Etawah (U.P.), India.

³Head of Department of Neurology, U.P. University of Medical Sciences, Saifai, Etawah (U.P.), India.

⁴Head of Department of Radiotherapy, U.P. University of Medical Sciences, Saifai, Etawah (U.P.), India.

***Corresponding Author: Anil Yadav**

Ph.D. Scholar, Radiographer (MRI/CT SCAN) & Guest Faculty (Deptt. of Radiological & Imaging Technology) Paramedical College, Saifai, Etawah (U.P.), India. Department of Radiology, U.P. University of Medical Sciences, Saifai, Etawah (U.P.), India.

Article Received on 23/10/2017

Article Revised on 14/11/2017

Article Accepted on 05/12/2017

ABSTRACT

In the world one- third population is infected with TB infection about 1% of the population each year. Tuberculosis of spine is mostly found in India. Imaging methodology is important for diagnosis of tuberculosis of spine. In our study of hundred patients of clinically suspected tuberculous-spondylitis were included into this planned study, during in this study December 2014 to November 2015. Among them, 100 cases of MRI and histology demonstrated and proven were incorporated in this study. The pinnacle frequency was observed to be in third decade (50%) with male predominance, 2.5 times more than female patients. The mean age was uncovered 35 years. Most noteworthy event was in double vertebrae inclusion (50%) alongside persistent vertebral contribution (85%). In this study destruction and collapse occur in most case (75%) with predominance with posterior element included (63%) and spinal deformation also was least (15%). Soft tissue of Para-spinal contribution was occur much of the time ((80%) with no calcification. Cord compression was 30%. MRI was an accurate and sensitive modality for the diagnosis of spinal tuberculosis.

KEYWORDS: Tuberculosis, Percival Pott, MRI, Transverse, Abscess, spinal Tuberculosis.**1. INTRODUCTION**

In developing countries, tuberculosis is very common. The most extrapulmonary location of tuberculosis is spine, accounting for more than 50% musculoskeletal tuberculosis.^[1] The first, Percival Pott initially depicted spine tuberculosis traditionally in 1778.^[2] Spine tuberculosis is the commonest type of skeletal tuberculosis and constitutes about 50% of all cases of TB of bones and joints. Tuberculous spondylitis now represents 6% of new extrapulmonary tuberculous cases.^[2] In developing nations, tuberculous spondylitis is an illness of kids, though in North America and Europe it is most common in moderately aged grown-ups. The disease is similarly conveyed between both (Male & females).^[3] Tuberculosis can influence diverse parts of vertebra. In a study where 122 cases were concentrated on the lesion included one area in 98 cases, 2 limitations (localization) in 9 cases and different confinements in 15 cases. The confinements were: posterior arch (20 cases), Centro somatic (10 cases), subligamentous (2 cases), sub-occipital (4 cases). Neurological inclusion was seen

in 51.5% of patients.^[4] In study of Dharmalingam (2004) demonstrated that the mean age of determination of tuberculous spondylitis was 36.5 and top occurrence is in the second decade of life (27.3%).^[4] In this study there were 24 male and 9 females. Most of the lesions included the dorsal spine (30.3%), trailed by the lumbar spine (27.2%) and skip sores was seen in 12.1% of cases. Associative tuberculosis of the lung was 66.6%.^[4] In the order of recurrence in Paus (1964) arrangement of 141 cases has been Lumbar (50), dorsal (35), dorso-lumbar (25), lumbo-sacral (22), cervico-dorsal (8), sacral (1) and cervical (nil).^[5] MRI is methodology of decision for the recognition, arranging, and differential analysis of incendiary issue of the spine, detached single vertebral body tuberculosis is seen in just 1.69% of the aggregate demonstrated cases of spine tuberculosis.^[6] Be that as it may, Paraspinal abscesses are available in 55% to 95% of cases.^[7] It permits the right determination to be made in all cases, exhibiting the pathological involvement of the Para vertebral structures and into spinal trench prior and more precisely than CT and plain radiography.^[8]

MRI Imaging of spinal diseases requires the utilization of combination of T1-weighted and T2-weighted or STIR sequence. Its scan checks perpetually indicate loss of cortical meaning of the influenced vertebrae. Nonetheless, influenced vertebrae are frequently in any event halfway kept up in pyogenic spondylitis. T1 weighted image regularly indicates contamination spread underneath the longitudinal tendons to include adjoining vertebral bodies. In some cases discs are relatively spared, especially in relationship to the level of bone destruction.^[9] MRI scanning is better diagnostic tools in current modality.^[10]

CEMR is valuable and characterizes Para spinal and epidural sickness. The point and target of the study is to discover age and sex rate among our populace and provincial appropriation rate in the spinal column and inclusion of number of vertebral involvement.

2. MATERIALS AND METHODS

This cross-sectional study was completed in the department of Radiology, UPUMS (formerly U.P.RIMS&R) Saifai, Etawah (U.P.) from December 2014 to November 2015. This study was done on 1.5 Tesla PHILIPS ACHIEVA NOVA MRI machine. Hundred patients showed up as tuberculous spondylitis

on clinical and X-Ray findings were included in this study. MRI was done for all patients and results were confirmed as the patients of spine TB by both systems.

Examination of spine was routinely performed in the sagittal and transverse planes by MRI. Sagittal images are gotten with T1 weighted and T2 weighted images by using SE (spin-echo) and FSE (fast spin-echo) techniques. Transverse images were obtained with T1 weighted SE sequence and FFE weighted sequence. Correlation of T1 and T2 weighted images was one of the crucial standards of image elucidation or interpretation. Intravenous GDTPA, CEMR improves MRI sensitivity for Intradural, intramedullary, neoplasm and inflammatory process. The techniques used for MRI of spine was showed as:

Cervical spine: Fig.1 (A & B).

- Survey
- Reference scan
- Sagittal T2 weighted FSE
- Sagittal T1 weighted SE
- Sagittal STIR
- Transverse T2 weighted FFE
- Transverse T1 weighted SE

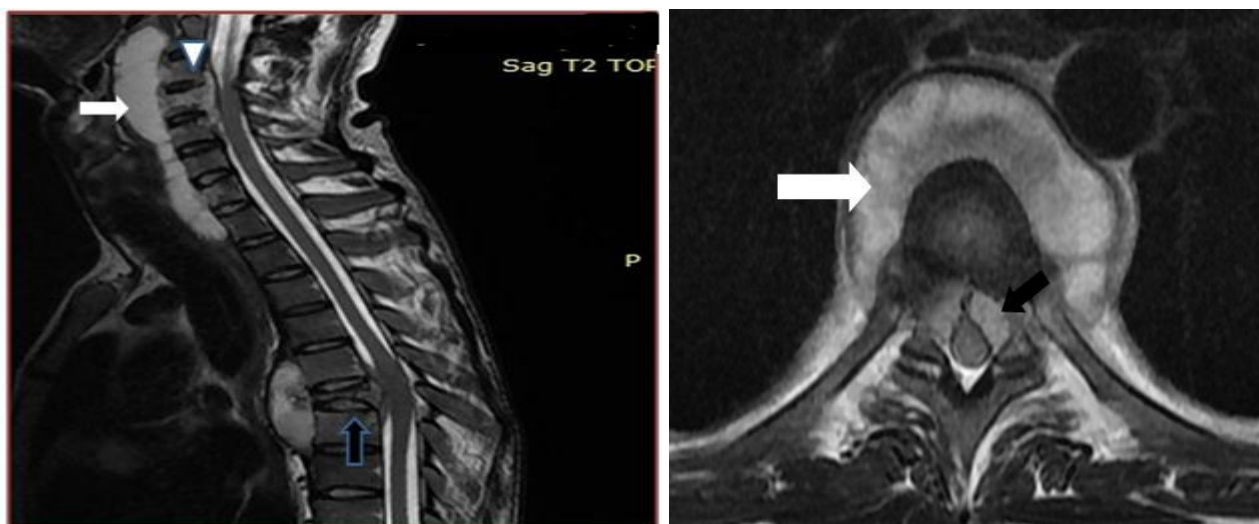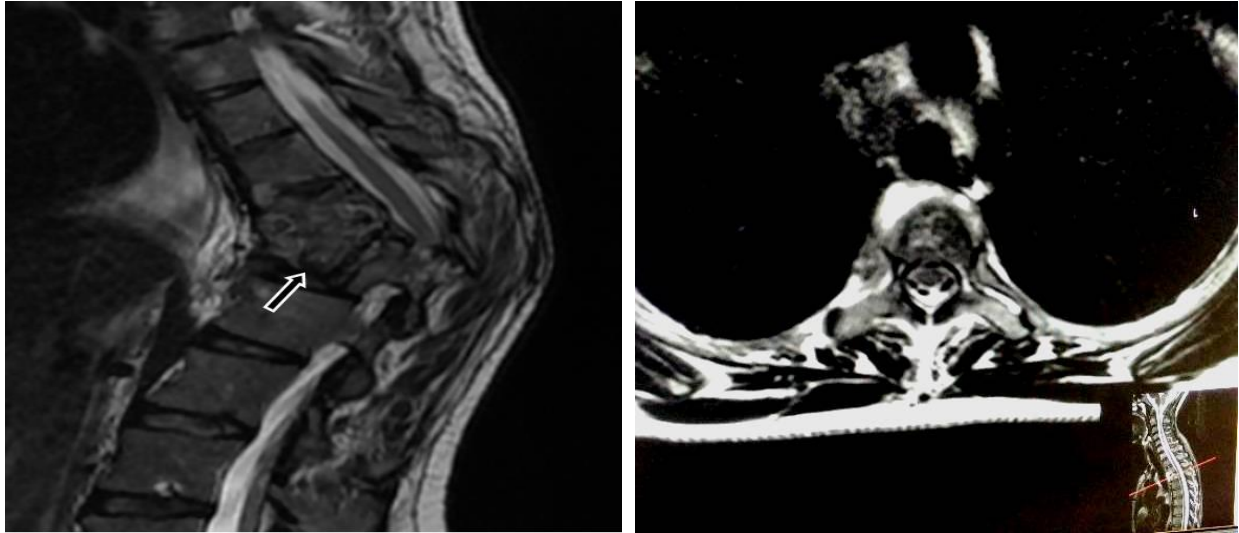


Figure 1: (A)

(B)

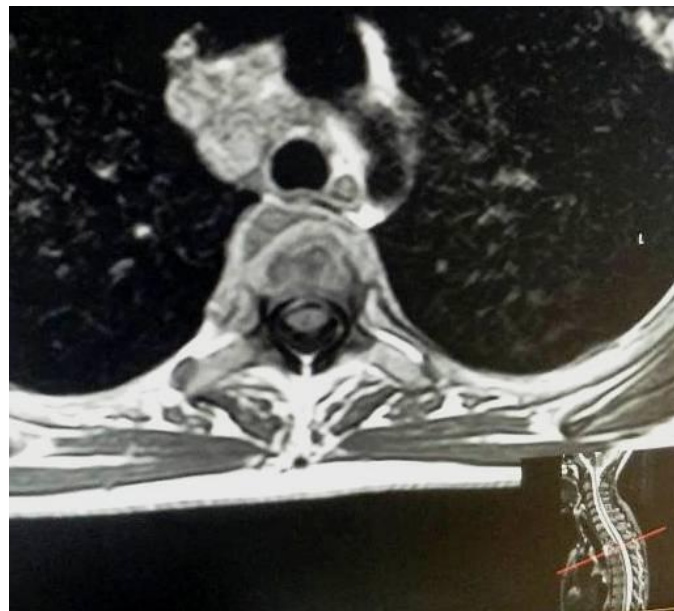
Dorsal spine: Fig.2. (A, B & C)

- Survey
- Reference scan
- Sagittal T2 weighted FSE
- Sagittal T1 weighted SE
- Sagittal STIR
- Transverse T2 weighted FSE
- Transverse T1 weighted SE

**Figure 2:**

(A)

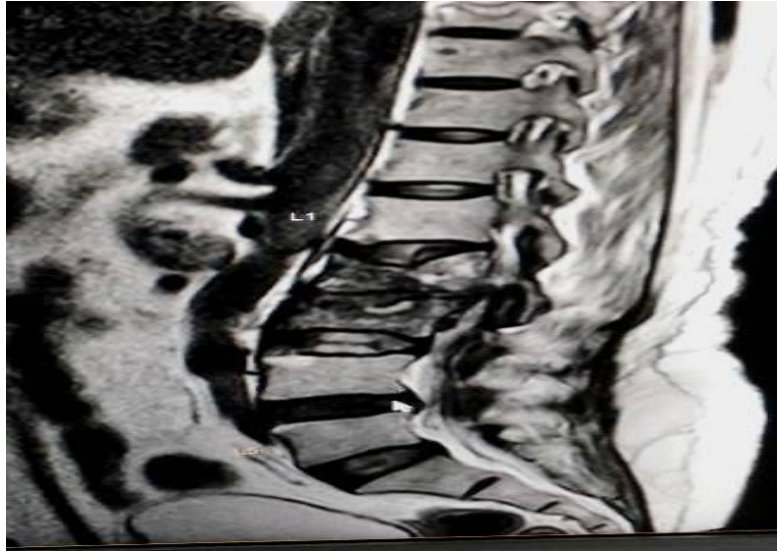
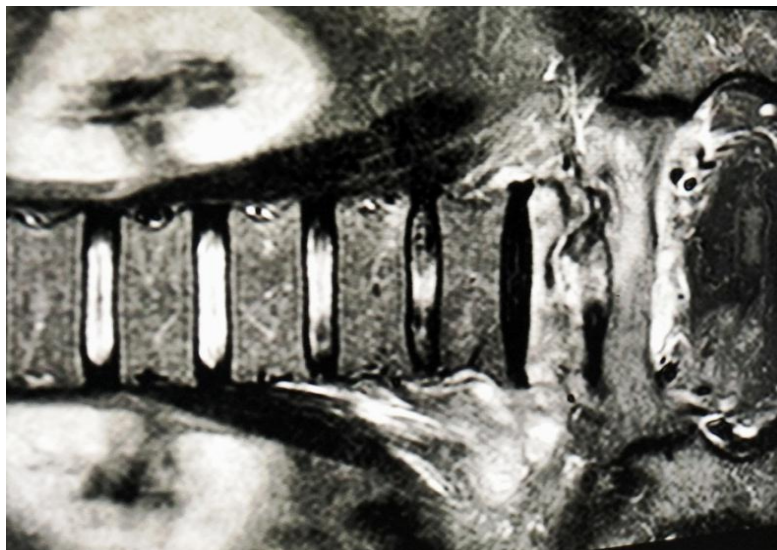
(B)



(C)

Lumbar spine: Fig. 3. (A & B)

- Reference scan
- Sagittal T2 weighted FSE
- Sagittal T1 weighted SE
- Sagittal STIR
- Transverse T2 weighted FSE
- Transverse T1 weighted SE
- Coronal T2 weighted TSE

**Figure 3: (A).****(B)**

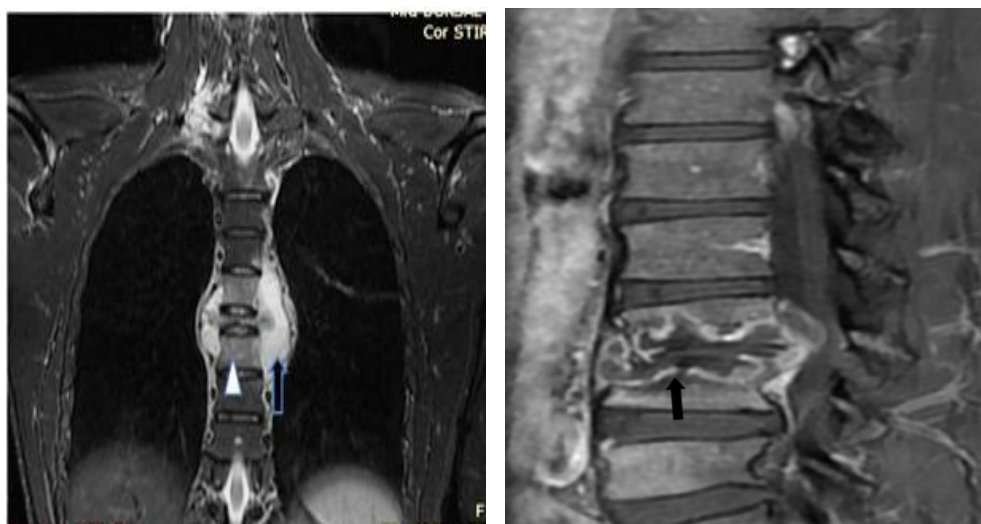
For contrast MRI: Fig.4.(A to E)

- Transverse T1 weighted
- Sagittal T1 weighted
- Coronal T1 weighted

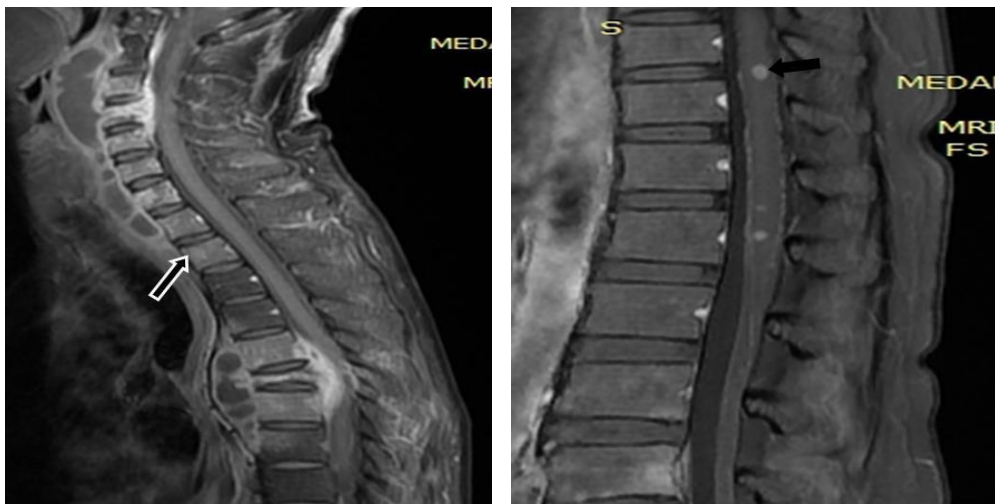

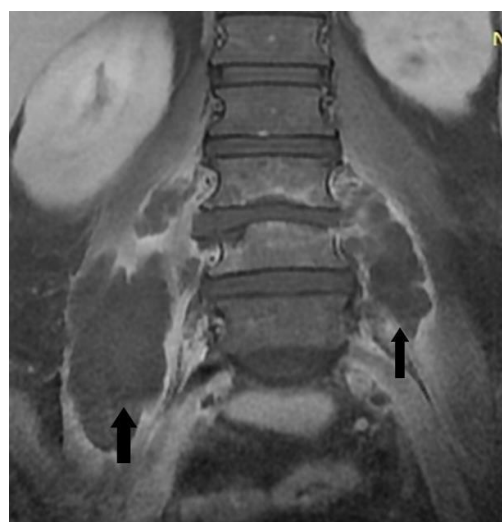
Figure 4: (A)

(B)



(C)

(D)



(E)

3. RESULTS

The aims and objectives of this study were only disclosed to the patients. It was assured that all data would keep hide and scanning would not mischief to the patient. Relevant information for every patient were gathered and recorded in pre-planned individual information accumulation sheet. Results come about Hundred (100) patients were chosen from 10 to 70 years old. The mean age was 30 ± 5 years. It was apparent that most elevated influenced people (37%) were between 31-40 years old took after by 15% in age go from 41-50 years. More established age aggregate (61-70) rather minimum influenced (5%).

Table 1: Patient's age-group percentage according to distribution.

Age-group	Distribution of Patients	Percentage (%)
10-20	10	10
21-30	25	25
31-40	37	37
41-50	15	15
51-60	8	8
61-70	5	5
Total	100	100

In our study 75 (75%) were male and 25 (25%) were female shown in figure 5.

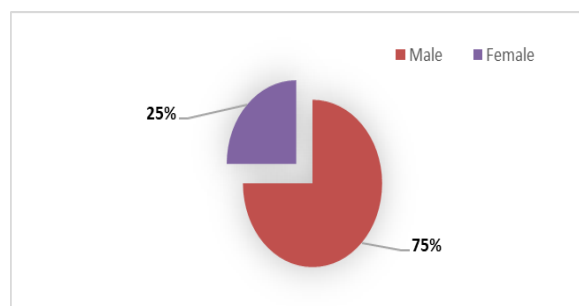


Figure 5: Distribution of sex.

In patients ten (10%) were neck pain, 65% were low spinal pain. Seventy (70%) had functional disability, 80% had fever and 10 % head deformity. None was experienced radiculopathy. MRI demonstrates regional vertebral inclusion. Ten (10%) had cervical involvement, 20% had upper thoracic contribution, in 30% cases bring down Dorsal vertebra and Dorso-lumbar vertebra, in 60 % cases of lumbar was included. No sacral piece was included.

Vertebrae was included single 10 (10%), double 50 (50%), three 25 (25%) more than three 15 (15%), persistent 85 (85%), non-consistent 15 (15%), decimation and collapse 75 (75%), none 25 (25%), posterior vertebrae involvement 63 (63%), non-involve 37 (37%), intra osseous abscess 50 (50%), signal change 95 (95%), no-signal change 5 (5%) and spinal distortion 15 (15%).

It was founding of soft tissue that epidural was 50 (50%), para-spinal 80 (80%), subligamentous 75 (75%), Myelitis 15(15%), cord compression 30 (30%) and calcification 0(0.0%).It was observed that thinning was 75 (75%), destruction 65(65%), endplate changes 65(65%) and single changes 80 (80%).

Here 93 (93%) cases of tuberculous spondylitis were accurately diagnosed, 5 (5%) cases were diagnosed accurately as not tuberculous spondylitis, 2 (2%) false negative cases, which were patient of tuberculous spondylitis, however analyzed as secondaries in the spine, in light of inclusion of pedicles. Here sensitivity and specificity of MRI were 98%. Here the accuracy of MRI in spinal tuberculosis was 98%.

4. DISCUSSION

Tuberculous spondylitis can happen in any age. Moderately aged grown-ups are the most every now and again influenced by tuberculous spinal infection.^[11] In this study, the most well-known age giving tuberculous spinal contamination is between 31 to 40 years (37%), which was not exactly the presentation in the developed nations. Since, lots of hazard components occurred for the improvement of tuberculosis, similar to, low nourishment, large amount of crowd, poor hygienic condition, multipariety and so forth. In western and developed nations, tuberculosis was a delayed presentation as on the grounds that, exclusive hazard calculate which assume important part for the improvement of this infection is immuno-compromised states like diabetes, hypertension, seniority and more recently AIDS. In comparison Males suffer more than females.^[12] In our study males were more sufferer than compression to females, around 3 times more than females. In this study, more than half of cases include lumbar vertebra, which is not contrasted from the perception by TK Loke.^[13] The single vertebral body inclusion found just 10% of cases, Single vertebral body association may emulate metastatic inclusion. It is likely that single vertebral body inclusion speaks to an early phase of illness and, in my experience, most cases will give propelled sickness because of its insidious onset. Inclusion of at least three vertebral bodies was found in half of my cases, more regular than in different series (15%) carried out by Smith.^[7] This reflects advanced disease and the course of transmission due to hematogeneous and subligamentous spread.^[14] The assortment of vertebral body contribution may bring about confusion with metastatic disease. Skip lesions situated at the cervical spine have been reported for in many as of 10% of cases.^[14] There might be a need to avoid non-contiguous lesions in the lower spine in those patients with cervical spondylitis, particularly when low back symptoms are available.

All TB spondylitis will demonstrate some type of vertebral body destruction. In our study, it is 65%. As far as my experience, transverse MR images will exhibit cortical destruction and back component contribution to

best favorable position. Back component involvement was found in 63% which is slightly more occurrence than that found in other reported series,^[13] despite the fact that it has been accounted for more regular in non-white population.^[15,16] There is an inclination towards pedicular and lamina contribution in tuberculous spondylitis, while pyogenic spondylitis has a preference for the facet joint.^[15] Bilateral pedicle inclusion is rare, however it brings about a non-stable spine and regularly requires an alternate approach.^[17] Posterior component contribution is every now and again observed as an extension of the vertebral body sickness, yet Babhulkar et al demonstrated that isolated illnesses of posterior component in tuberculous spondylitis have a reported occurrence running from 0.8 to 10%.^[18]

There is regularly a hyperintense signal intensity of the vertebral body contiguous the included plate on T2 weighted images. Like other spinal diseases, a hyperintense signal on T1 weighted image from already influenced vertebrae shows healing, found to connect well with clinical signs and symptoms.^[19] signal change with hyper intensity on short TR/TE that is seen with healed or chronic TB because of penetration of hemopoietic marrow with fat, furthermore been accounted for to happen as ahead of schedule as 1 month, making MRI possibly extremely helpful for observing the impacts of chemotherapy. It has been reported for that thick edge enhancement in these abscesses is strongly suggestive of tuberculous contamination and is not seen in non-granulomatous spondylitis.^[19]

Most of the active infection has paraspinal soft tissue masses. MR imaging is especially helpful in showing the morphologic degree of soft tissue spread, particularly after GdDTPA injection. Paraspinal abscesses are regularly respective, extensive and moderately out of extent to the measure of bone destruction.^[20,21]

GdDTPA MRI is especially helpful for characterizing tuberculous spondylitis. Thick rim improvement around intra osseous and para-spinal soft tissue abscesses has not been shown in other spinal disease.^[19] Gero demonstrated that epidural expansion and intradural infection are seen to better preferred advantage on improved scan.^[22] Abscesses versus cellulitis is frequently determined to have certainty simply after GdDTPA enhancement found in presence of reactivation. Both abscesses and cellulitis demonstrate comparative signal intensities on unenhanced T1 and T2 weighted images and their differentiation is important on the grounds that abscesses require drainage. Post proposed that in pyogenic spondylitis, thick enhancement of vertebral body with GdDTPA enhancement in MR imaging seems to show an active infection, while insignificant or irrelevant complexity medium take-up is demonstrative of determining infection.^[23]

MR imaging is valuable in the detection of reactivation of chronic tuberculous spondylitis. The presence of

active sickness is shown as vertebral body destruction, particularly with concomitant para-spinal soft tissue and additionally intra osseous abscesses.

Vertebral body and disc improvement might be seen after GdDTPA intravenous contrast. MR imaging should be thought to be the imaging methodology of decision for patients with suspected TB spondylitis, in view of its high specificity, sensitivity and accuracy as it gives necessary information to the specialist for appropriate management by giving vertebral intra osseous abscess, vertebral disc crumple, skip sores, dural and intradural infections and inclusion of back components.

ACKNOWLEDGEMENT

We are thankful to Dr. (Brig.) T. Prabhakar, Vice Chancellor, Dr. (Brig.) S.K. Gupta, Medical Superintendent and the department of Radiology, UPUMS, Saifai, Etawah, India. We are also thankful to Dr. Neeraj Tandan, Executive Director, Scientific & Applied Research Centre (SARC) Meerut, Uttar Pradesh, India.

5. REFERENCE

- Hodgson AR, Skinsness OK, Leong CY. The pathogenesis of spinal TB paraplegia. *J Bone Joint Surg Am*, 1967; 49: 1147-56.
- Thrush A., Enzmann D. Magnetic Resonance Imaging of infectious spondylitis, *AJNR*, 1990; 11:1171-1180.
- Tuli SM (Editor). *TB of the skeletal systems*. 2 ed. Delhi: Jaypee, 1997; 5-14.
- Dharmalingam M. Pott's spine-Sabah experience. *Epidemiology, treatment and results, TB*, 2004; 84: 24-28.
- Paus P. Treatment for TB of the spine, *ACTA Ortho (Suppl)*, 1964; 72.
- Lolge S., Maheshwari M., Shah J., Patkar D., Chawla A. Isolated solitary vertebral body tuberculosis, study of seven cases, *Clin Radiol*, 2003; 58: 545-50.
- Smith AS, Weinstein MA, Mizushima A, Coughlin B, Hayden SP et al. MR imaging characteristics of tuberculous spondylitis vs vertebral osteomyelitis, *AJR*, 1989; 153: 399-405.
- Ridley N., Shaikh MI., Remedios D., Mitchell R. *Radiology of skeletal TB, Orthopaedics*, 1998; 21: 1213-1220.
- Zamiati W., Jiddane M., el Hassani MR., Chakir N., Boukhrissi N. Contribution of spiral Computed Tomography and MRI in spinal TB, *J Neuroradiol*, 1999; 26: 27-34.
- Osborn AG. (Editor). *Diagnostic Neuroradiology*. 1st edition. Missouri: Mosby, 1994; 822-824.
- Sharif HS. Role of Magnetic Resonance Imaging in the management of the spinal infections, *AJR*, 1992; 158: 1333-1345.
- Liu GC., Chou MS., Tsai TC, Lin SY., Shen YS. MR evaluation of tuberculous spondylitis, *Acta*

- Radiol 1993;34:554-8. Desai SS. Early diagnosis of spinal tuberculosis by MRI, *J Bone Joint Surg Br*, 1994; 76: 863-9.
13. Loke TK., Ma HTG., Chan CS. Magnetic Resonance Imaging of the tuberculous spinal infection, *Australas Radiol*, 1997; 4: 7-12.
 14. Weaver P., Lifeso RM. The radiological diagnosis of tuberculosis of the adult spine, *Skeletal Radiology*, 1984; 12: 178.
 15. Chapman M., Murray RO., Stoker DJ. TB of the bones and joints, *Semin. Roentgenol*, 1979; 14: 266-82.
 16. Naim Ur-Rahman. Atypical forms of spinal tuberculosis, *J. Bone Joint Surg*, 1980; 62: 162-5.
 17. Travlos J., du Toit G. Spine tuberculosis: Beware the posterior elements, *J. Bone Joint Surg*, 1990; 72: 722-3.
 18. Babhulkar SS., Tayade WB., Babhulkar SK. Atypical spine tuberculosis, *J. Bone Joint Surg*, 1984; 66: 239-42.
 19. Sharif HS., Clark DC., Aabed MY., Haddad MC., Al Deeb SM et al. Granulomatous spinal infections: Magnetic Resonance Imaging, *Radiology*, 1990; 177: 101-107.
 20. Whelan MA., Naidich DP., Post JD., Chase NE. C.T of spinal tuberculosis, *J. Comput. Assist. Tomogr*, 1983; 7: 25-30.
 21. La Berge JM., Brant Zawadzki M. Evaluation of Pott's disease (Spinal tuberculosis) with computed tomography, *Neuroradiology*, 1984; 26: 429-434.
 22. Gero B., Sze G., Sharif H. Magnetic Resonance Imaging of intradural inflammatory diseases of the spine, *AJNR*, 1991; 12: 1009-19.
 23. Post MJD., Sze G., Quencer RM., Eismont FJ., Green BA., Gahbauer H. Contrast enhanced MRI in spine infection, *J. Comput. Assist. Tomogr*, 1990; 14: 721-9.