wjpmr, 2018,4(1), 177-182

SJIF Impact Factor: 4.103

WORLD JOURNAL OF PHARMACEUTICAL AND MEDICAL RESEARCH

www.wjpmr.com

Research Article

ISSN 2455-3301

WJPMR

CLINICOPATHOLOGICAL STUDY AND MANAGEMENT OF NON-TRAUMATIC GASTROINTESTINAL PERFORATION- A HOSPITAL BASED STUDY

M. R. Attri[1], Ajaz Ahmad Shah*[1], Irfan Nazir Mir[1], Jubran Amain[2], Firdous Hamid[1], Mir Mujtaba Ahmad[3] and Hilal Ahmad Wani[1]

[1]Department of Surgery, GMC Srinagar, J&K, India.
[2]Department of Pathology, GMC Srinagar, J&K, India.
[3]Department of Surgery, HIMSAR, New Delhi, India.

***Corresponding Author: Ajaz Ahmad Shah**

Department of Surgery, GMC Srinagar, J&K, India.

Article Received on 20/11/2017 **Article Revised on 11/12/2017** **Article Accepted on 01/01/2018**

ABSTRACT

Introduction: Non-traumatic hollow viscus perforation is one of the most common surgical emergencies. Surgical interventions (laparotomy) is warranted in almost all cases. **Objectives:** (i) Evaluate the etiological factors of hollow viscus perforation commonly presenting in a tertiary hospitals. (ii) Evaluate the accuracy of history, clinical parameters, laboratory and radiological investigations in the diagnosis and further management. **Methods:** This hospital based prospective study was conducted in the Postgraduate Department of General Surgery, Government Medical College, Srinagar for two consecutive years from August 2015 to September 2017 in cases undergoing, laparotomy for non-traumatic hollow viscus perforations **Result:** Majority of our patients were in their 3rd and 4th decade of life. Out of a total of 272 patients, male contributed 238 (87.5%) while as females were only 34 (12.5%). A total of 171 (62.86%) cases of gastroduodenal perforations were encountered in the present study followed by 61 (22.42%) appendicular cases. 30 (11.02%) of patients had small gut perforations while as 10 (3.67%) patients had colorectal perforations. In duodenal perforation, duodenal ulcer was the commonest etiology, malignancy was the commonest etiology in gastric ulcer perforation. Typhoid fever was the commonest etiology in ileal perforation. In the present study free gas under right dome of diaphragm was present in 215 (79.05%) patients. Patients included in this study were managed according to the standard protocols, initial resuscitation was followed by definitive surgery. **Conclusion:** Gastrointestinal perforations have a good prognosis provided they are diagnosed and operated early because of its dramatic onset. Closure of the perforation is still thecommonest surgical procedure done in ileal perforations followed by thorough peritoneal toilet withnormal saline.

KEYWORDS: Perforation, Peritonitis, Resuscitation.

INTRODUCTION

Perforation of a hollow viscus from wide variety of causes comprises the major portion of emergency surgical admissions and emergency laparotomies.[1,2] The diagnosis and treatment of gastrointestinal perforations remains main problem in our country.[3] Improved medical and surgical care has reduced this problem in North America and the U.K., where vascular lesions and malignancies are predominant cause of perforations, while in our country, peptic ulcer disease, typhoid and tuberculosis are still preceding malignancies.[4] Especially these days, the inadvertent use of NSAIDS and other over the counter analgesics forms one of the most common risk factors.[5] Perforations of the duodenum, stomach and small bowel form a considerable proportion of emergency work load than colonic perforations.[6] The perforation of a hollow viscus leads to contamination of peritoneal cavity. This can lead to an infective process, sepsis, disseminated intravascular coagulation, multi-system organ failure (MSOF) and even death in the presence of irreversible damage to the vital organs.[7] Plain, supine and erect radiographs of the chest and abdomen are recognized as the most appropriate first-line investigations when a perforation of a viscus is considered.[8] Majority of patients present with sudden onset of abdominal pain.[9] A high index of suspicion is essential to diagnose visceral perforation early, as significant morbidity and mortality results from diagnostic delay.[10]

Operative management depends on the cause of perforation, general condition of the patient, site of perforation, number of perforations and degree of peritoneal soiling.[11] Surgical options include; primary closure of perforation, wedge resection of area and closure, resection of bowel with anastomosis, closure of perforation and entero-enteric anastomosis and enterostomy (ileostomy or colostomy).[12]

Gastrointestinal perforations account for about 25% of acute abdominal emergencies and are still associated with considerable morbidity and mortality. The largest number of cases in any series are peptic in etiology, but typhoid constitutes a significant group and tuberculosis bringing up the rare.[13]

No age is immune to perforation and has been reported in an infant 2 month old and a woman 77 years old.[14] Perforation of peptic ulcer occurs most frequently in the third and 4th decades of life and the prognosis is more favourable in those under 40 years of age. Predominance of perforation in males has been mentioned by almost every author and male to female ratio figuring 3:1 to 12:1.[15] Pain which is acute as chief presenting symptoms has been mentioned by most of the authors. 98.7% of gastric and 99.1% of duodenal cases sought admission to the hospital for pain.[16] Pain may be complained of in epigastrium, right upper quadrant, right shoulder or may be even generalized.[13]

Vomiting has been mentioned as the next most frequent symptom in perforated gastro duodenal ulcer and featured in half the number of cases.[16] Tenderness and rigidity are the most common physical signs. High temperature with an increased pulse rate points towards developing peritonitis. Presence of pneumoperitoneum has been found in more than 80% by most of the authors.[13,15]

A perforation of stomach may be caused by a peptic ulcer that is acute or chronic or by a carcinomatous ulcer and if only simple suturing of a gastric ulcer perforation is feasible because of patients condition, a biopsy of the ulcer should be taken, preferably by excision. If the biopsy fails to show carcinoma, follow up by barium studies is essential, because 6% apparently simple perforated gastric ulcers were found to be either carcinomatous or lymphomas by Wilson.[17] The incidence of bowel perforation in typhoid fever varies markedly from place to place and also appears to be changing with time. The highest quoted incidence being 17.9%.[18] Typhoid perforation is commoner in men and those under 40 years of age.[19] Tuberculosis may involve the gastrointestinal tract from duodenum to anus but most commonly involves the terminal ileum and caecum, which are commonest sites for perforation.[20] Simple closure of perforation was recommended by Conjalka.[21]

Farnelins (1567) was first to report a case of perforated appendicitis. Wegeler (1813) and Prescott (1815) described perforated appendicitis. No difference between genders were found in various age groups.[22] Pain localized or diffuse is the common feature with association of repeated vomiting in perforated appendicitis.[23]

Perforation of colon has been known since early times. It has been recorded in Bible. Malignancy contributes 21% of cases having colonic perforations.[24] Perforation in ulcerative colitis has been reported and is common after steroid therapy or in initial attack of disease.[25]

Thus the present study has been undertaken with an interest to find the clinical features, etiological factors, common type of perforations and their presentations, operative modalities and postoperative complications that occurred in these patients.

AIMS AND OBJECTIVES

1. Evaluate the etiological factors of hollow viscus perforation commonly presenting in a tertiary hospitals.
2. Evaluate the accuracy of history, clinical parameters, laboratory and radiological investigations in the diagnosis and further management.

MATERIAL AND METHODS

This hospital based prospective study was conducted in the Postgraduate Department of General Surgery, Government Medical College, Srinagar for two consecutive years August 2015 to September 2017 in cases undergoing, laparotomy fornon-traumatic hollow viscus perforations.

Inclusion criteria

Patients with abdominal pain and features of peritonitis, generalized or localized suspected of having hollow viscus perforation (duodenum, stomach, small intestine and large intestine) were included.

Exclusion criteria

1. Patient with traumatic hollow viscus perforations diaganosed clinically and radiologically.
2. Perforation of abdominal part of esophagus.
3. Billiary tree perforations.
4. Patients with perforations of genitourinary tract like urinary bladder rupture, female reproductive tract.

The details of patients' complaints, clinical examination and investigations were recorded in a specially designed proforma. Informed/ written consent was taken from each patient before the start of study.

The patients included in the study were subjected to a thorough history elicitation, physical examination with relevant investigations like Routine blood examination including complete hemogram, blood grouping and typing, HIV, HBsAg, blood urea, serum creatinine, serum electrolytes, and urine examination. Erect abdomen X-ray to detect free gas under diaphragm (lateral decubitus X-ray in unstable patients), Widal's test was done in suspected enteric perforations, four quadrant abdominal paracentesis was done only in selected cases (just for confirmation in cases where X-ray shows no gas under the diaphragm), Ultrasonography and CECT abdomen was also performed if required. All patients confirmed by above history, clinical examination and investigative procedures were subjected to emergency laparotomy.

Statistical Method

The recorded data was compiled and entered in a spreadsheet (Microsoft Excel) and then exported to data editor of SPSS Version 20.0 (SPSS Inc., Chicago, Illinois, USA). Continuous variables were summarized as Mean±SD and categorical variables were expressed as number and percentages. Graphically the data was presented by bar and pie diagrams.

RESULTS AND ANALYSIS

Majority of our patients were in their 3rd and 4th decade of life comprising of 171 (62.87%) followed by 77 (28.30%) patients aged 41-60 years (Table-1).

Table 1: Age distribution of study patients.

Age in Years	No. of Patients	Percentage
<20	13	4.78
21-40	171	42.87
41-60	77	28.30
60-80	11	4.05
Total	**272**	**100.00**

Out of a total of 272 patients, male contributed 238 (87.5%) while as females were only 34 (12.5%).

Table 2: Incidence of Gastrointestinal Perforations.

Site of Perforation	No. of Patients	Percentage
Gastroduodenal	171	62.86
Small gut	30	11.02
Appendicular	61	22.42
Colon and rectum	10	3.67
Total	**272**	**100.00**

A total of 171 (62.86%) cases of gastroduodenal perforations were encountered in the present study followed by 61 (22.42%) appendicular cases. 30 (11.02%) of patients had small gut perforations while as 10 (3.67%) patients had colorectal perforations (Table-2).

Table 3: Etiology and site of Gastroduodenal Perforations.

Etiology	Duodenal	Gastric	Ileal	Appendix	Colon
Acid peptic	115	4	0	0	0
Malignancy	0	6	0	0	8
Drug intake / smoking	31	6	0	0	0
Typhoid	0	0	25	0	0
Alcohol	5	0	0	0	0
Tuberculosis	0	0	3	0	0
Meckel's	0	0	1	0	0
Idiopathic	4	0	1	61	2

In duodenal perforation, duodenal ulcer was the commonest etiology, malignancy was the commonest etiology in gastric ulcer perforation. Typhoid fever was the commonest etiology in ileal perforation. Majority of the patients presented within 24 hours in which 160 (58.62%) reached within 13-24 hours, 80 (29.41%) patients reached within 12 hours and 32 (11.76%) patients took more than 24 hours to present after the onset of symptoms (Table-3).

Table 4: Various Clinical Features in Gastrointestinal Perforations.

Symptoms & Signs		No. of Patients	Percentage
Pain		272	100.00
Vomiting		202	74.26
Pyrexia		230	84.55
Distension		172	63.23
Constipation		10	3.5
Diarrhoea		65	23.89
Tenderness	All quadrants	172	63.23
	Right iliac fossa	100	36.76
Rigidity		272	100.00
Absence of liver dullness		219	80.51
Free fluid		230	84.55
Absent bowel sounds		230	84.55
Gas under diaphragm		215	79.04
Fluid levels		57	20.95
Diagnostic paracentesis		50	18.38
Positive blood widal		22	8.08

In the present study all the patients presented with all signs and symptoms mentioned in the table (Table-4). Gas under diaphragm were present in 215 patients, typhoid fever was the main symptom in ileal perforation. In all cases of ileal perforation gas under diaphragm was present and widal was positive in 22 of 24 patients.

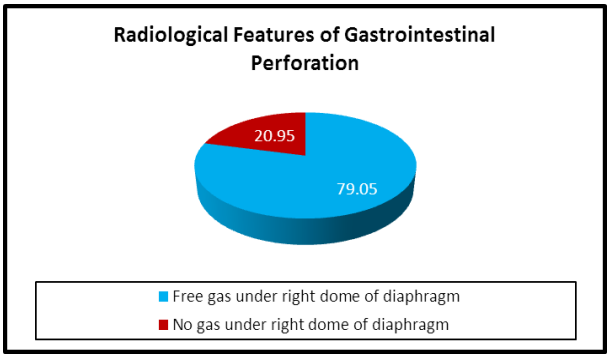

Figure 1: In the present study free gas under right dome of diaphragm was present in 215 (79.05%) patients.

Table 5: Diagnosis and surgical procedures done.

Diagnosis	Surgical Procedure	No. of Patients
Duodenal ulcer	Closure of perforation with omental patch and peritoneal lavage	155
Gastric ulcer	Closure of perforation with omental patch and peritoneal lavage	12
	Gastrectomy with gastrojujenostomy	4
Terminal ileal perforation (typhoid)	Primary closure of ileal perforation with peritoneal lavage	26
	Tubercular ileal perforation	3
Meckel's	Diverticulectomy with end to end ileal anastomosis	1
Appendix	Appendicectomy with peritoneal lavage	61
Colon	Right colon (right hemicolectomy with ileotransverse anastomosis)	5
	Left colon (left hemicolectomy with transverse loop colostomy)	3
	Rectosigmoid (primary closure of rectosigmoid perforation with transverse loop colostomy)	2

Patients included in this study were managed according to the standards measures, preoperative resuscitative measures in case of shock and correction of electrolyte abnormality were carried out in all patients. After preoperative treatment all cases were subjected to laparotomy and primary cause was identified and treated accordingly (Table-5).

As far as complications are concerned, 75 of our patients had wound infections, fetal fistula was seen in 1 patients while as 2 of our patients expired

DISCUSSION

In our study, majority of our patients were in their 3rd and 4th decade of life comprising of 171 (62.87%) followed by 77 (28.30%) patients aged 41-60 years. Our results are comparable with the findings of Velappan DP et al (2017)[26]

Out of a total of 272 patients, male contributed 238 (87.5%) while as females were only 34 (12.5%). Males were also dominant in a study done by Mewara BC et al (2017)[27] with 89 males and 11 females. Males were again more in number i.e. 77 in comparison to females i.e. 13 in a study done by Velappan DP et al (2017)[26]

The patients taken up for this study came from various parts of Kashmir province. The majority of patients belonged to urban i.e. 150 (55.15%). We could not found any literature suggesting geography of the patients.

A total of 171 (62.86%) cases of gastroduodenal perforations were encountered in the present study followed by 61 (22.42%) appendicular cases. 30 (11.02%) of patients had small gut perforations while as 10 (3.67%) patients had colorectal perforations. Most common site of perforation was gastroduodenal in 62% patients followed by appendicular perforation in 16% of patients studied by Velappan DP et al (2017)[26] which is again true with the findings of Kumar Vinod et al (2014)[28] In duodenal perforation, duodenal ulcer was the commonest etiology, malignancy was the commonest etiology in gastric ulcer perforation. Typhoid fever was the commonest etiology in ileal perforation. Perforation is a rare complication of gastric carcinoma account for less than 1%. Perforated gastric ulcer have high incidence of malignancy [Roviello Franco et al (2006)[29] Majority of the patients presented within 24 hours in which 160 (58.62%) reached within 13-24 hours, 80 (29.41%) patients reached within 12 hours and 32 (11.76%) patients took more than 24 hours to present after the onset of symptoms. 90 patients presented within 24 hours and out of them 60 presented within 13 to 24 hours of the onset of symptons (Velappan DP et al, 2017).[26]

In the present study all the patients presented with all signs and symptoms with abdominal pain, vomiting,

distention, fever, constipation and diarrhoea. Gas under diaphragm were present in 215 patients, typhoid fever was the main symptom in ileal perforation. In all cases of ileal perforation gas under diaphragm was present and widal was positive in 22 of 24 patients. All cases of with duodenal ulcer perforation in a study done by Velappan DP et al (2017)[26] presented with all signs and signs which were presented in our patients like abdominal pain, vomiting, fever, distention, constipation which was again comparable with the findings of Kamal Ahmad Saeed et al (2015)[30] In the present study free gas under right dome of diaphragm was present in 215 (79.05%) patients which is comparable with the findings of Velappan DP et al (2017)[26] wherein gas under diaphragm was present in 75 (75%) patients.

Patients included in this study were managed according to the standards measures, preoperative resuscitative measures in case of shock and correction of electrolyte abnormality were carried out in all patients. After preoperative treatment all cases were subjected to laparotomy and primary cause was identified and treated accordingly.

CONCLUSION

Gastrointestinal perforations have a good prognosis provided they are diagnosed and operated early because of its dramatic onset. The majority of perforation peritonitis cases in the study comprised of peptic ulcer perforations followed by appendicular and small bowel perforations. The basic principles of early diagnosis prompt resuscitation and urgent surgical intervention still form the cornerstones of management in these cases. Laparotomy and closure of perforation with omentalpatching done in stomach and duodenal perforation withperitoneal toilet that is omental patching, the commonestsurgical procedure done in the peptic perforations. Closure of the perforation is still thecommonest surgical procedure done in ileal perforations followed by thorough peritoneal toilet withnormal saline.

REFRENCES

1. Arthur DJ, Thomas V, Berne, John DA. Perforated duodenal ulcer - An alternative therapeutic plan. Arch Surg., 1998; 133: 1166-1170.
2. Beniwal US. Comparative study of operative procedures in typhoid perforations. Ind J Surg, 2003; 65(2): 172-176.
3. Christiansen J. Perforated duodenal ulcer managed by-simple closure versus closure and proximal vagotorny. Prospective study of 50 cases. Br J Surg, 1987; 74(4): 286-287.
4. Dorairajan LN, Gupta S, Suryanarayana Deo SV, Chumber S, Sharma LK. Peritonitis in India - A decade's experience. Trop Gastroenterol, 1995; 16: 33-38.
5. Inderbir S. Oesophagus, stomach and intestine. Textbook of human histology, 2nd edition, published by Jaypee Brothers Medical Publishers, 1994; 212-225.
6. Jhobta RS, Attri AK, Kaushik R, Sharma R. Spectrum of perforation peritonitis in India – review of 504 consecutive cases. World J Em Surg, 2006; 1: 1186-1749.
7. Tripathi MD, Nagar AM, Srivastava RD, Partap VK: Peritonitis- study of factors contributing to mortality. Indian J Surg, 1993; 55: 342-49.
8. Butler J, Martin B. Towards evidence based emergency medicine: best BETs from the Manchester Royal Infirmary. Detection of pneumoperitoneum on erect chest radiograph. Emerg Med J., 2002; 19(1): 46-7.
9. Nair SK, Singhal VS, Kumar S. Non-traumatic intestinal perforation. Ind J Surg., 1981; 43(5): 371-378.
10. Playforth MJ, McMahom MJ. The indication of simple closure of perforated duodenal ulcer. Br J Surg., 1978; 65: 699-701.
11. Sorsi GA, Richard H, Turnage. 'Appendicitis in Gastrointestinal and liver disease. Pathophysiology and diagnosis / management 7th edition edit by Sleisenger and Fordtran's., 2002; 2: 2089-2096.
12. Bailey and Love's Short Practice of Surgery, 25th edition, p 994, summary box 58.5, p69. 13. CRC Press, Taylor and Francis Group.
13. Bhansali SK. Gastro intestinal perforations. J Postgrad Med, 1967; XII: 1-2.
14. Gilmour J, Saint JH. Acute perforated peptic ulcer.Br J Surg, 1032; 20; 78-89.
15. Coggon A, Lambert P, Langman MJ. 20 years of hospital admissions for peptic ulcer in England and Wales. Lancet, 1981; 1: 1302.
16. Kozoll BO, Meyer KA, General factors influencing incidences and mortality of acute perforated duodenal ulcers. Surg Gynecol Obstet, 1960; 3: 607-25.
17. Wilson Maedonald J, Mortensen NJM, Williamson RCN. Perforated gastric ulcer. Postgrad Med J, 1984; 71: 774.
18. Fisher RP, Miller Crotchett P, Reed RL. Hazards of non-operative management in adults with blunt abdominal injury. J Trauma, 1988; 28: 1145.
19. Archamong EO. Operative treatment of typhoid perforation of the bowel. Br Med J, 1969; 26: 207-30.
20. Rajagopalan AE, Pickleman J, free perforations of small intestine. Ann Surg, 1982; 196: 576-79.
21. Conjalka MS, Usselman J. Successful treatment of tuberculosis. Mt Sinai J Med, 1980; 47: 283-84.
22. Anderson R, Hugander A, ThulinA et al. Indications for operations in suspected appendicitis and incidence of perforation. Br Med J, 1994; 808: 107.
23. Baily and Love. Acute appendicitis. A Short Practice of Surgery Lewis HK Co, Ltd. London, 1975.
24. Goligher JC, Moir PS, Wrigley PH. The Billroth I and polya operations A comparison. Lancet, 1956; 1: 220-26.

25. Brooke BN. Simplified operative routine for carcinomatous obstruction of the colon. Lancet, 1955; 1: 945-46.
26. Velappan DP, Kaveri S. Clinical study and management of hollow viscus perforation of abdomen. Int Surg J, 2017; 4(5): 1773-1776.
27. Mewara BC, Chourashiya BK, Porwal S, et al. A Clinical Study of the Spectrum of Gastro Intestinal Perforation Peritonitis in Rural Southern East Rajasthan. J Univer Surg, 2017; 5: 2.
28. Vinod Kumar B, Mathew AS. Clinical study of abdominal hollow visceral perforation-non traumatic. J Evolution of Med and Dent Sci., 2014; 3(30): 8366-8371.
29. Franco Roviello, Simone Rossi, Daniele Marrelli, Giovanni De Manzoni, Corrado Pedrazzani, Paolo Morgagni, Giovanni Corso and Enrico Pinto. Perforated gastric carcinoma: a report of 10 cases and review of the literature. World Journal of Surgical Oncology, 2006; 4: 19.
30. Kamal Ahmed Saeed and Kamal Aziz Abdulqadr. Non-traumatic gastrointestinal Sperforation as a cause of acute abdomen. JSMC, 2015; 5(1): 89-84.