



DIFFERENT METHODS OF AGE DETERMINATION

Dr. Saba Bilal¹, Dr. Danish Ali², Dr. Zill E. Huma^{*3}¹PMDC # 68227-S.²PMDC # 87642 -P.³PMDC # 85469-P.

*Corresponding Author: Dr. Zill E. Huma

PMDC # 85469-P.

Article Received on 20/03/2018

Article Revised on 10/04/2018

Article Accepted on 30/04/2018

ABSTRACT

Age estimation provides a valuable tool in forensic cases. Various methods like morphological age, secondary sexual characters, skeletal age indicators and dental age indicators are used in the forensic investigation as well as in medicolegal cases. Morphological age and secondary sexual characters are not reliable factors for age estimation whereas skeletal age and dental age indicators provide valuable information. This article explains different methods of age estimation.

KEYWORDS: Age estimation, Morphological age, Secondary Sexual Characters, Skeletal age indicators and Dental age indicators.

INTRODUCTION

The identity of an individual can be established by determining the age. The Anthropologists, Archaeologist and forensic scientist mostly use age estimation procedures for legal, social, paleo-demographic and forensic investigations.^[2] Age estimation is routinely used procedure for activities like for employment, retirement, property management, insurance claims, passport verification, voting right and disputed marriages as also other judicial matters of both civil and criminal nature.^[5] The chronologic age of a person is the age measured at a given point of time from a known date of birth.^[4] Chronological age gives an approximate idea of the growth a person. Different types of maturity markers used to estimate age are.^[7]

1. **Morphological Age.**
2. **Secondary sexual characteristics**
3. **Skeletal Age**

Sutures (Coronal Suture, Fronto-lacrimal suture, Fronto-ethmoid suture, Zygomatico-maxillary suture, Zygomatico-temporal suture, Spheno-frontal suture, Spheno-temporal suture, Sagittal suture, Pterion, Squamous suture, Parietomastoid suture, Occipitomastoid suture, Lambdoid suture), Ossification of cervical vertebrae, Medial end of clavicle, Head of humerus, Distal end of radius, Third and fourth joint of sacrum, Lateral joint of sacrum, Iliac crest, Head of femur, Distal end of femur, Distal end of tibia.

4. Dental Age (DA)

- Tooth eruption
- Tooth mineralization assessed from dental radiographs
- Histological methods
- Biochemical Methods e.g. Amino Acid
- Racemization, C14 analysis
- Coronal - Pulp Cavity Index

1. Morphological Age

Physiological age is also called as the biological/developmental age. It describes the individual growth status. It is usually determined by estimating the morphological age, secondary sexual characteristics, psychological development, skeletal age and dental age.^[6] The physiological age was initially measured by the height of an individual and termed as the *morphological age*. The factors like malnutrition and various diseases can influence height. Hence morphological age should not be used solely to determine the age of an individual.^[7]

2. Skeletal Age Estimation

The bones in the human body are developed from a number of centers of ossification and growth. At the prenatal stage of life, 806 centers of bone growth are there. At birth near about 450 remains and an adult has 206 bones. Total 600 centers of bone growth disappear because they coalesce or unite with nearby centers. In the normal human skeleton, this process of disappearance and union of bones has a sequence and time and hence

make it a reliable age indicator.^[3] An overview of the appearance and union of centers of ossification as seen

radiographically was proposed by *Flecker* (1942)^[3] is depicted in Table # 1.1.

Table 1.1: Chronological Order of Appearance and Fusion of Epiphysis (Flecker 1942).^[3]

Before birth		
Both	Appearance	Head of humerus, distal femur, proximal tibia, calcaneus, talus
Females	Appearance	Cuboid
During the first month		
Both	Appearance	Hamate, capitate, head of femur, third cuneiform.
Females	Appearance	Capitulum, distal radius, distal tibia, distal fibula.
Males	Appearance	Cuboid
During the second month		
Both	Appearance	Proximal phalange of inner four fingers.
Females	Appearance	First metacarpal, distal phalanges of thumb, middle, and ring fingers, tarsal navicular, first and second cuneiforms.
Males	Appearance	Capitulum, distal epiphysis of radius, distal fibula.
At age of two		
Both	Appearance	Inner four metacarpals, first metatarsal, proximal phalanges of toes, distal phalanx of hallux.
Females	Appearance	Proximal phalanx of thumb, middle row of phalanges of fingers.
Males	Appearance	First metacarpal, distal phalanx of thumb and distal phalanx of index, first cuneiform.
At age of three		
Females	Appearance	Patella, proximal fibula, second metatarsal, third metatarsal, middle phalange of second, third and fourth toe, distal phalanges of third and fourth toe.
Males	Appearance	Triquetrum, proximal phalanx of thumb, middle phalanges of middle and ring fingers, tarsal navicular, second cuneiform.
At age of four		
Both	Appearance	Fourth metatarsal
Females	Appearance	Head of radius, fifth metatarsal
	Fusion	Greater tubercle to head of humerus
Males	Appearance	Lunate, middle phalanges of index and little fingers, distal phalanges of middle and ring fingers, second metatarsal, third metatarsal, middle phalanx of second toe.
At age of five		
Both	Appearance	Carpal navicular, multangulum majus, greater tochanter, distal phalanx of second toe.
Females	Appearance	Medial epicondyle, distal ulna, lunate, triquetrum, multangulum minus, distal phalanx of index
At age of five		
Males	Appearance	Head of radius, distal phalanx of little finger, patella, proximal fibula, fifth metatarsal, middle phalanges of third and fourth toe, distal phalange of third and fourth toe.
	Fusion	Greater tubercle to head of humerus
At age of six		
Male	Appearance	Medial epicondyle, distal ulna, multangulum minus.
At age of seven		
Female	Appearance	Distal phalanx of little finger
	Fusion	Rami of ischium
At age of eight		
Both	Appearance	Apophysis of calcaneus
Female	Appearance	Olecranon
At age of nine		
Female	Appearance	Trochlea, pisiform
Males	Appearance	Rami of ischium and pubis
At age of ten		
Male	Appearance	Trochlea, olecranon
At age of eleven		
Females	Appearance	Lateral epicondyle

Males	Appearance	Pisiform
At age of twelve		
Males	Appearance	Lateral epicondyle
At age of thirteen		
Females	Appearance	Proximal sesamoid of thumb
	Fusion	Lower conjoint epiphysis of humerus, distal phalanx of thumb, bodies of ilium, ischium, and pubis.
Males	Fusion	Capitulum to trochlea and lateral epicondyle.
At age of fourteen		
Females	Appearance	Acromion, iliac crest, lesser trochanter.
	Fusion	Olecranon, upper radius, proximal phalanx of ring fingers, distal phalanx of thumb, head of femur, greater trochanter, distal tibia and fibula, apophysis calcaneus, first metatarsal, proximal phalanges of toe.
Males	Appearance	Proximal sesamoid of thumb, base of fifth metatarsal.
At age of fifteen		
Both	Appearance	Sesamoid of little finger.
	Fusion	Distal phalanges of second, third, and fourth toe.
Females	Appearance	Sesamoid of index and little fingers.
	Fusion	Medial epicondyle, first metacarpal, proximal phalanx of thumb, distal phalanges of inner four fingers, proximal tibia, outer four metatarsal, middle phalanx of second toe, distal phalanges of inner four toe.
Males	Appearance	Acromion
	Fusion	Ilium, ischium, and pubis.

Table 1.2: Appearance of Ossification Centers after Five Years of Age.

Sr. No.	Bone	Beginning	Complete fusion
1	Humerus, proximal	17-20 years	24 years
2	Radius, distal	17-18 years	23 years
3	Ulna, distal	17-20 years	23 years
4	Femur, distal	17-18 years	22 years
5	Tibia, proximal	17-18 years	23 years
6	Fibula, proximal	17-18 years	22 years
7	Iliac crest, epiphysis	17-21 years	23-25 years
8	Clavicle, medial	18-25 years	31 years
9	Closure of basilar suture	17-18 years	20-21 years

3. Secondary Sexual Characteristics A sequence of events are involved during Puberty like gradual physical changes, hormonal, reproductive, and emotional changes. The secondary sexual characteristics also appear during puberty like breast development, pubic hair, genital development, axillary hair growth, facial hair growth and voice change. Once sexual maturity is attained, these features are of no use to estimate age. Puberty is also unreliable for age estimation because it is affected by malnutrition, hormonal imbalance and ethnicity.^[7]

4. Dental age

a) Tooth eruption

The English law (1836) specified the age limit i.e. 7 years of age at which a person is legally responsible for crimes. The criminal who didn't have a record of their age was forwarded to the medical practitioner to know whether their third molar had protruded. The Factories Regulation Act (1833) was passed to limit the number and working hours of child labor in mills. The act stated that child could not be employed before 9 years of age

and their working hours were restricted until 13 years of age. In lower socioeconomic classes, it was difficult to get birth registration records and hence their physical age and appearance was used to identify their age. As stated above that physical or morphological age is not a clear indication of age, *Sir Edwin Saunders* (1837) suggested using eruption sequence of permanent teeth from seven to fourteen years of age.^[1]

Tooth eruption in the oral cavity is affected by a number of factors such as space available, ankyloses, and early or delayed exfoliation of the primary tooth. These factors ultimately change tooth eruption pattern of permanent teeth and hence makes it an unreliable source of age estimation.^[1]

b) Tooth mineralization

In this method, calcification of tooth is used for age estimation. Tooth calcification is divided into different developmental stages according to different authors. It has ranged from 22 stages to 3 stages. Few authors have

stated that fewer stages of tooth calcification result in better inter-examiner interpretation but less precision.

The method which uses more stages results in precise estimation but poor repeatability.^[7]

Table 1.3: Number of Tooth Developmental Stages by Different Authors.

Sr. No.	Authors	Year	Sample size	Number of stages
1	Schour and Massler	1941	Unknown	22
2	Gleiser and Hunt	1955	50	17
3	Garn et al.	1959	255	3
4	Hotz et al.	1959	298	11
5	Nolla	1960	50	11
6	Moorrees et al.	1963	345	14
7	Nanda and Chawla	1966	720	12
8	Haavikko (modification of Gleiser and Hunt)	1970	1162	12
9	Johanson	1971	155	7
10	Liliequist and Lundberg	1971	287	8
11	Demirjian	1973	2928	8
12	Gustafson and Koch	1974	41	4
13	Rosen (modification of Schour and Massler)	1981	760	19-22
14	Nortje	1983	500	8
15	Gat	1984	196	6
16	Kullman	1992	677	7
17	Mesotten et al. (modification of Gleiser and Hunt)	2002	1175	10
18	Sarnat	2003	693	7

The age estimation determined by tooth mineralization gives results within approximately 2 years, with a 95% confidence interval, due to the individual variation in tooth development.^[11]

1) Histological and Biochemical methods

- Gustafson's technique
- Incremental lines of Retzius
- Prenatal and postnatal line formation
- Racemization of collagen in dentin
- Cemental incremental lines
- Translucency of dentin

Coronal pulp cavity index:^[8] The correlation between the reduction of the coronal pulp cavity and the chronological age was examined in a sample of eight hundred and sixty-four intact teeth from four hundred and thirty-three individuals of known age and sex using panoramic radiographs. For each radiograph, only mandibular premolars and molars were considered, as the mandibular teeth are more visible than the maxillary ones. The side where the pulp chamber was more visible was chosen. Panoramic radiography was used to measure the length (mm) of the tooth crown (CL, coronal length) and the length (mm) of the coronal pulp cavity (CPCH, coronal pulp cavity height or length). The tooth-coronal index (TCI) was computed for each tooth and regressed on the real age of the sample.

$$TCI = \frac{CPCH \times 100}{C^L}$$

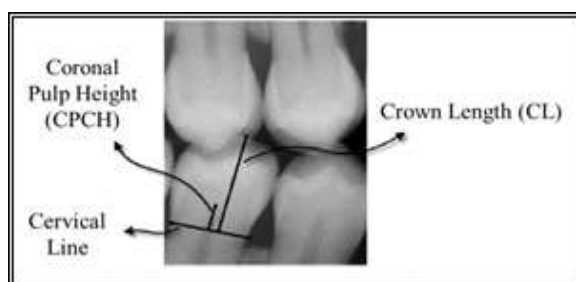


Fig. 1: Coronal Pulp cavity Index.

Simple linear regression analysis was carried out by regressing the proportional coronal pulp cavity length on the actual age for each group of teeth for males and females and for the combined sample.

The correlations were significant especially for molars in males ($r = -0.92$, $R^2 = 0.85$).

r = (Linear correlation coefficient): It measures the strength and the direction of a linear relationship between two variables.

R^2 = (Coefficient of determination): It gives the proportion of the variance (fluctuation) of one variable that is predictable from the other variable. It is a measure that allows determining how certain one can be in making predictions from a certain model/graph.

The regression equations are as follows

Premolars

- $Y = 77.617 - 1.4636 \times \text{combined sample}$
- $Y = 79.679 - 1.5356 \times \text{males}$
- $Y = 75.523 - 1.3896 \times \text{females}$

Molars

4. $Y = 76.073 - 1.4576 x$ combined sample
5. $Y = 77.747 - 1.5066 x$ males
6. $Y = 73.846 - 1.3906 x$ females

8. A.G. Drusini. The Coronal Pulp Cavity Index: A Forensic Tool for Age Determination in Human Adults: *Cuad Med Forense*, 2008; 14(53-54): 235-249.

Three regression equations (one for the males, one for the females and one for the genders combined) were tested on a random sample of 100 teeth (50 premolars and 50 molars). The best results were obtained for the male molars, with an error of ± 5 years in 81.4% of the cases. No significant difference exists between the teeth of the right and the left side, and between first and second premolar and first and second molar. The interobserver error was found out to be 3.8%.

SUMMARY

To conclude, age estimation is important in a number of medicolegal situations. There are many ways to identify a person's age but each method has its own pros and cons. Therefore firm guidelines could not be formed for age estimation. These methods should be chosen wisely to estimate age to assure the quality standards and adequate answers to the important legal and social issue of age estimation in forensic science.

REFERENCES

1. Andreas Schmeling, Pedro Manuel Garamendi, Jose Luis Prieto and María Irene Landa. Forensic Age Estimation in Unaccompanied Minors and Young Living Adults. In: *Forensic Medicine – From Old Problems to New Challenge* ISBN: 978-953-307-262-3.
<http://www.intechopen.com/books/forensicmedicine-from-old-problems-to-newchallenges/forensic-age-estimation>.
2. Arthur B., Lewis, Stanley M. Garn. The relationship between tooth formation and maturational factors. *Angle Orthodontics*, April, 1960; 30(2): 70 – 77.
3. Francis CC, Werle PP. The appearance of centers of ossification from birth to five years. *American journal of physical anthropology*, 1939; 24: 273-299.
4. Manisha M. Khorate, A. D. Dinkar, Junaid Ahmed: Accuracy of age estimation methods from Orthopantomographs in forensic odontology: A comparative study. *Forensic Science International*, 2014; 234: 184.e1–184.e8.
5. Mincer HH, Hanis EF, Berryman HE. The ABFO study of third molar development and its use as an estimator of chronological age. *J Forensic Science*, 1993; 38: 379-90.
6. Rana Modassir Shamsher Khan, Abida Ijaz. Correlation of Dental Calcification and Skeletal Maturity Indicator. *Annals*, January – March, 2011; 17(1): 22-26.
7. Susan Parekh Dental Age Assessment – Developing Standards for UK Subjects Division of Craniofacial Development UCL Eastman Dental Institute, 256 Gray's Inn Road London WC1X 8LD UK, 2011.