

NON-HODGKIN B-CELL LYMPHOMA OF THE OVARY – A CASE REPORT

Dr. O. El Allam*, S. EL Majjaoui, I. Bourhafour, A. Semmar, T. Kibdani and N. Benjaafar

Department of Radiation Oncology, National Institute of Oncology, Mohammed 5 University Rabat, Morocco.

*Corresponding Author: Dr. O. El Allam

Department of Radiation Oncology, National Institute of Oncology, Mohammed 5 University Rabat, Morocco.

Article Received on 25/04/2018

Article Revised on 16/05/2018

Article Accepted on 06/06/2018

ABSTRACT

The ovarian lymphoma is very rare. We report a case of diffuse large B-cell lymphoma of the ovary manifesting as advanced ovarian cancer. The diagnosis was confirmed on histological and immunohistochemical analysis. The patient was treated with surgery followed by chemotherapy using 8 cycles of R-CHOP regimen. A consolidative radiation therapy was delivered to the bulky mediastinal disease.

KEYWORDS: Diffuse large B cell lymphoma, Lymphoma, Ovarian tumour.

INTRODUCTION

The ovarian lymphoma is rare. Lymphoma presenting as an ovarian mass is even rarer. We report a case of Non-Hodgkin's Lymphoma of right ovary, which was managed by surgery, chemotherapy and radiotherapy.

CASE REPORT

A 19-year-old woman presented with a history of painless abdominal swelling of 3 months. Upon clinical examination an abdominal mass with restricted mobility was detected in the right iliac fossa. Laboratory studies showed elevated levels of CA125 and LDH, 311 U/mL and 414 IU/L, respectively. A pelvic MRI revealed a right ovarian mass measuring 81mm × 84mm × 130mm. The mass was removed completely. The surgery included a right salpingoophorectomy along with omentectomy and peritoneal cytology. Immunohistochemical evaluation showed strong staining for CD20 and bcl-2. These same cells were negative for CD3 and CD10 (Figure-1). The diagnosis of diffuse large B-cell lymphoma was made. After operation, a CT of neck,

chest, abdomen and pelvis showed mediastinal bulky and para-aortic lymph nodes. A bone marrow biopsy showed no abnormalities.

A chemotherapy protocol comprising 8 cycles of R-CHOP regimen was administered to the patient. An evaluation after 4 cycles was made, showing a partial response according to the criteria of CHESON 1999. A second evaluation was made six weeks after the end of chemotherapy using 18F-FDG PET-CT. It's revealed moderate uptake by the residual mediastinal masse SUV max= 2.67. It was superior than SUVmax normalized to liver uptake.

Involved-node radiation therapy was given to the bulky mediastinal mass using a dose of 30 Gy (in 15 fractions), with a 6 Gy (in 3 fractions) boost to the residual disease.

Therapeutic response was obtained with PET/CT, 15 weeks after the completion of radiation therapy. The abnormal uptake has disappeared.

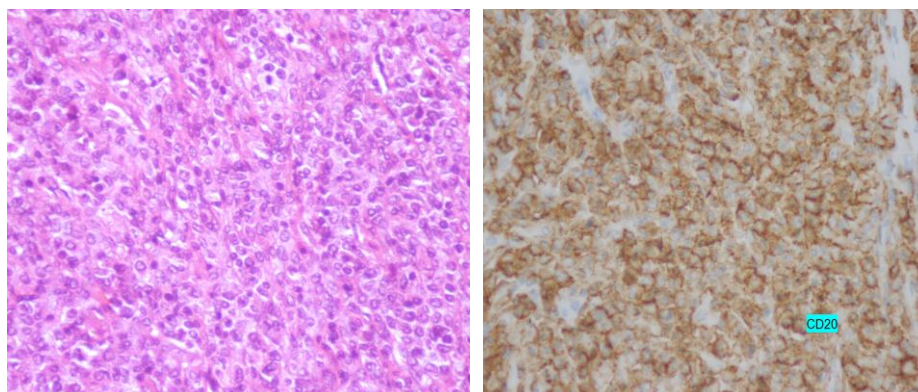


Fig-1: Diffuse infiltration of malignant lymphoid cells stained with CD20.

DISCUSSION

Ovarian non-Hodgkin's lymphoma (NHL) accounts for 1.5% of all ovarian neoplasm and 0.5-1% among all NHL.^[1,2] The difference between primary and secondary lymphomas is important in terms of prognosis. Secondary ovarian lymphoma is more aggressive as 5 years survival rate is 33% whereas it is 80% in primary lymphoma.^[3] Fox et al. Proposed the following criteria for the diagnosis of primary ovarian NHL.^[4] (a) At the time of diagnosis, the lymphoma is clinically confined to the ovary and a complete investigation fails to reveal evidence of lymphoma elsewhere. However, an ovarian lymphoma can still be considered as primary if it has spread to immediately adjacent lymph nodes or if it has directly spread to infiltrate immediately adjacent structures. (b) The peripheral blood and bone marrow should not contain any abnormal cells. (c) If further lymphomatous lesions occur at sites remote from the ovary, then at least several months should have elapsed between the appearance of the ovarian and extraovarian lesions. When these criteria are applied, our case can be considered as secondary ovarian NHL. Lymphomas of the ovary may have varied presentations such as abdominal or pelvic mass or pain, weight loss, weakness, vaginal bleeding, ascites and sometimes constitutional symptoms. B symptoms were noted in 10%–33% of the patients.^[5-7] In our case, patient presented with a 3 months history of gradual abdominal pain without B symptoms. Diffuse large B-cell lymphoma appears to be the most common type of ovarian NHL.^[8] The histology in our case was reported to be consistent with diffuse large B-cell lymphoma and immunohistochemical evaluation showed strong staining for CD20 and Bcl2. Ki67 was positive, showing high proliferative index.

Initial treatment usually involves bilateral salpingo-oophorectomy, although unilateral salpingo-oophorectomy may be acceptable if there is no evidence of disease on the contralateral side after careful inspection.

R-CHOP chemotherapy is given according to stage as an adjuvant treatment of ovarian diffuse large B-cell NHL.^[9,10]

The role for radiation in bulky sites of advanced stage diffuse large B cell lymphoma is less certain. Nevertheless, consolidative RT might improve survival in patients with a residual mass after chemotherapy.^[11,12]

CONCLUSION

Non-Hodgkin B-Cell Lymphoma of the Ovary is a rare entity and it must be differentiated from other ovarian malignancies as its management and prognosis differ significantly from them. Treatment regimen mainly consists of chemotherapy (CHOP) associated with rituximab. Consolidation RT appears to decrease the risk of local disease progression and overall relapse rates in patients with bulky disease.

REFERENCES

1. Chorlton I, Norris HJ, King FM. Malignant reticuloendothelial disease involving the ovary as a primary manifestation: a series of 19 lymphomas and 1 granulocytic sarcoma. *Cancer*, 1974; 34(2): 397-407.
2. Elharroudi T, Ismaili N, Errihani H, Jalil A. Primary lymphoma of the ovary. *J Cancer Res Ther.*, 2008; 4(4): 195-6.
3. Crasta JA, Vallikad E. Ovarian lymphoma. *Indian J Med Paediatr Oncol.*, 2009; 30(1): 28-30.
4. Fox H, Langley FA, Govan AD, Hill AS, Bennett MH. Malignant lymphoma presenting as an ovarian tumour: a clinicopathological analysis of 34 cases. *Br J Obstet Gynaecol*, 1988; 95(4): 386-90.
5. Senol T, Doger E, Kahramanoglu I, Geduk A, Kole E, Yucesoy I, et al. Five cases of non-hodgkin B-cell lymphoma of the ovary. *Case Rep Obstet Gynecol*, 2014; 2014: 392758.
6. Dimopoulos MA, Daliani D, Pugh W, Gershenson D, Cabanillas F, Sarris AH. Primary ovarian non-Hodgkin's lymphoma: outcome after treatment with combination chemotherapy. *Gynecol Oncol*, 1997; 64(3): 446-50.
7. Monterroso V, Jaffe ES, Merino MJ, Medeiros LJ. Malignant lymphomas involving the ovary. A clinicopathologic analysis of 39 cases. *Am J Surg Pathol*, 1993; 17(2): 154-70.
8. Vang R, Medeiros LJ, Warnke RA, Higgins JP, Deavers MT. Ovarian non-Hodgkin's lymphoma: a clinicopathologic study of eight primary cases. *Mod Pathol*, 2001; 14(11): 1093-9.
9. Sehn LH, Donaldson J, Chhanabhai M, Fitzgerald C, Gill K, Klasa R, et al. Introduction of combined CHOP plus rituximab therapy dramatically improved outcome of diffuse large B-cell lymphoma in British Columbia. *J Clin Oncol*, 2005; 23(22): 5027-33.
10. Pettengell R, Linch D, Haemato-Oncology Task Force of the British Committee for Standards in H. Position paper on the therapeutic use of rituximab in CD20-positive diffuse large B-cell non-Hodgkin's lymphoma. *Br J Haematol*, 2003; 121(1): 44-8.
11. Held G, Murawski N, Ziepert M, Fleckenstein J, Poschel V, Zwick C, et al. Role of radiotherapy to bulky disease in elderly patients with aggressive B-cell lymphoma. *J Clin Oncol*, 2014; 32(11): 1112-8.
12. Fluge Øystein et al. Consolidative Radiotherapy to Residual Masses After Chemotherapy Is Associated With Improved Outcome in Diffuse Large B-Cell Lymphoma. A Retrospective, Population-Based Study. *Clin Lymphoma Myeloma Leuk*, 2018 Feb; 18 (2): 125.