

**SPINDLE CELL CARCINOMA OF MANDIBULAR GINGIVA: REPORT OF AN UNUSUAL CASE**

Dr. O. El Allam\*, K. Benali, I. Bourhafour, S. El Majjaoui, T. Kebdani and N. Benjaafar

Department of Radiation Oncology, National Institute of Oncology, Mohammed 5 University Rabat, Morocco.

**\*Corresponding Author: Dr. O. El Allam**

Department of Radiation Oncology, National Institute of Oncology, Mohammed 5 University Rabat, Morocco.

Article Received on 24/09/2018

Article Revised on 15/10/2018

Article Accepted on 05/11/2018

**ABSTRACT**

Spindle cell carcinoma is a rare highly malignant squamous cell carcinoma. Here, we describe a case of a 33-year-old female who presented with history of pain and swelling in the left mandibular region. Histological analysis revealed spindle squamous cell carcinoma and surgical resection alone was performed initially. A re-excision was made followed by adjuvant chemoradiotherapy after recurrence.

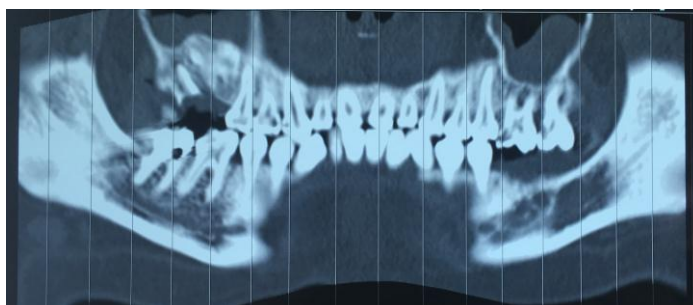**KEYWORDS:** Mandible, sarcomatoid carcinoma, spindle cell carcinoma, prognosis, treatment.**INTRODUCTION**

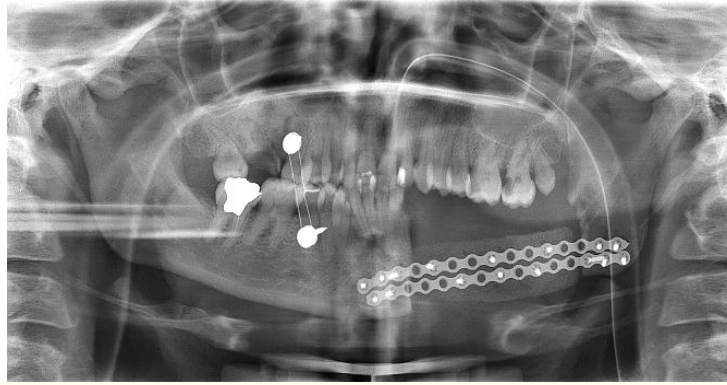
Spindle cell carcinoma is a biphasic tumor composed of a squamous cell carcinoma and a malignant spindle cell component with a mesenchymal appearance, but of epithelial origin.<sup>[1]</sup> Spindle cell carcinomas have been reported from diverse sites such as upper aerodigestive tract, esophagus, salivary glands, thyroid, thymus, lung, breast, gastrointestinal tract, hepatobiliary system, genitourinary tract and uterus. The most common site of origin in the head and neck region is the glottis and hypopharynx.

**CASE REPORT**

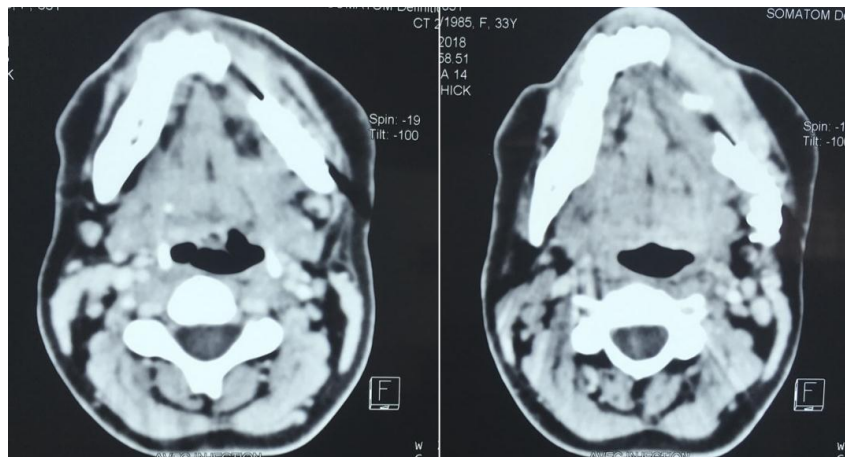
A 33-year-old woman presented with a history of a hard, nonmobile, painless mass in the left mandibular region. The patient had discovered the mass incidentally two months earlier, but reported no paraesthesia or limitation of mouth opening and food intake at that time. Intraoral examination revealed missing jaw teeth and a 40 mm × 40 mm, poorly defined and indurated tumour without tenderness. No cervical lymphadenopathy was noted. Panoramic radiography revealed diffuse bone loss in the left mandibular body. The focus range was about 40 mm

× 35 mm, its edge uneven, and the cortical bone eroded and destroyed (Figure 1). The incisional biopsy of the lesion was performed under local anesthesia. The histopathological examination showed spindle shaped cells. Most tumor cells showed an increasing mitotic activity as well as pleomorphism. Immunohistochemical investigations of tumor cells showed positivity for creatine kinase, vimentin and for EMA. Tumor cells were also focally positive for AE1/3. Based on immunohistochemical findings a diagnosis of Spindle cell carcinoma was made. The patient underwent partial mandibulectomy and mandibular reconstruction using a bridging plate (Figure 2). Histopathology and immunohistochemistry of excised specimen confirmed the diagnosis of Spindle cell carcinoma. Internal and external margins were microscopically involved. The patient did not receive subsequent chemotherapy and postoperative irradiation. Four months later there was a recurrence. A CT scan was performed confirming the recurrence (Figure 3). A re-excision was made followed by adjuvant chemoradiotherapy (66 Gy in 33 daily fractions with concurrent cisplatin chemotherapy 40 mg/m<sup>2</sup> on a weekly basis).

**Fig-1: Panoramic radiograph shows a diffuse irregular osteolytic bone destruction in the mandible.**



**Fig-1: Panoramic radiograph shows partial mandibulectomy and mandibular reconstruction using a bridging plate.**



**Fig-3: Axial CT images showing the recurrence on the tumor bed.**

## DISCUSSION

Spindle cell carcinoma is a type of malignant mixed tumor that is extremely rare in the mandible. The sarcomatous components are derived from the squamous epithelium with divergent mesenchymal differentiation.<sup>[2]</sup> The oral cavity and larynx are predominant sites for Spindle cell carcinoma in the head and neck region.<sup>[3]</sup> The main features of sarcomatoid carcinoma are: (a) the tumour is of epithelial origin; and (b) both the epithelial and mesenchymal cell differentiations exist morphologically. Among a large number of spindle cells, malignant epithelial components such as transitional cell carcinomas, squamous cell carcinomas, adenocarcinomas or anaplastic carcinomas are visible. Ultrastructurally, a transitional zone exists between the carcinomatous and sarcomatous components, the latter generally accounting for > 50% of the lesion.<sup>[4,5]</sup>

Immunohistochemical staining shows that the sarcomatous components express epithelial markers, which are important for the diagnosis of Spindle cell carcinoma. In addition to the expression of the mesenchymal marker VIM, sarcomatous components occasionally express muscle cell or Schwann cell markers such as SMA, actin, neuron-specific enolase and

S100 protein, and often express the epithelial marker CK or epithelial membrane antigen.<sup>[5,7-8]</sup>

Because of the rarity of the disease, no standard diagnostic and treatment approach are available at the moment. However, wide surgical excision alone or with adjuvant (chemo)radiotherapy seems to be the most successful therapeutic modality specially in the cases with high risk features i.e. stage III and IV, positive/unclear margins, extracapsular spread and vascular/perineural invasion. Despite that, the prognosis is poor with a median survival of 18 months.<sup>[9]</sup>

## CONCLUSION

Spindle cell carcinoma follows aggressive clinical course and is defined by malignant histopathologic features requiring immunohistochemistry for diagnosis. It is important to be aware of this type of neoplasm to ensure early detection and develop appropriate clinical management strategies by further studies.

## REFERENCES

1. Barnes, Leon, et al, eds. *Pathology and genetics of head and neck tumours*, 2005; 9: IARC.
2. Batsakis, John G., and Patricia Suarez. "Sarcomatoid carcinomas of the upper aerodigestive

- tracts." *Advances in Anatomic Pathology*, 2000; 7(5): 282-293.
3. Batsakis, John G., Dale H. Rice, and Donald R. Howard. "The pathology of head and neck tumors: spindle cell lesions (sarcomatoid carcinomas, nodular fasciitis, and fibrosarcoma) of the aerodigestive tracts, Part 14." *Head & neck surgery*, 1982; 4(6): 499-513.
  4. Thompson, Lester DR, et al. "Spindle cell (sarcomatoid) carcinomas of the larynx: a clinicopathologic study of 187 cases." *The American journal of surgical pathology*, 2002; 26(2): 153-170.
  5. Wick, Mark R., Jon H. Ritter, and Peter A. Humphrey. "Sarcomatoid carcinomas of the lung: a clinicopathologic review." *American journal of clinical pathology*, 1997; 108(1): 40-53.
  6. Nagayoshi, Junichi, Takashi Kawakami, and Yoshio Maruyama. "Sarcomatoid carcinoma of the ureter: a case report." *International journal of urology*, 1997; 4(6): 618-620.
  7. Wright, Jonathan L., et al. "Differences in survival among patients with sarcomatoid carcinoma, carcinosarcoma and urothelial carcinoma of the bladder." *The Journal of urology*, 2007; 178(6): 2302-2307.
  8. Cornette, Jerome, W. A. Tjalma, and Philippe Buytaert. "Biphasic sarcomatoid carcinoma or carcinosarcoma of the breast: prognosis and therapy." *European journal of gynaecological oncology*, 2005; 26(5): 514-516.
  9. Iqbal, Muhammad Shahid, et al. "Spindle cell carcinoma of the head and neck region: treatment and outcomes of 15 patients." *ecancermedicalscience*, 2015; 9.