

AN UNUSUAL CASE OF A LARGE INCISIONAL HERNIA PRESENTING WITH ACUTE PANCREATITIS

Sabreen Elbakri, Zen Yong and Darren J. Porter*

Ninewells Hospital and Medical School, Dundee, Scotland, United Kingdom.

*Corresponding Author: Dr. Darren J. Porter

Ninewells Hospital and Medical School, Dundee, Scotland, United Kingdom.

Article Received on 15/10/2018

Article Revised on 05/11/2018

Article Accepted on 26/11/2018

ABSTRACT

We report an unusual case of an 83year old lady presenting with acute pancreatitis due to a large incisional hernia containing the second part of the duodenum and the ampulla causing mechanical obstruction of the pancreatic duct and the common bile duct. Surgical management was not undertaken due to the patient's age and functional status. She was managed conservatively and was discharged following clinical improvement and normalisation of laboratory tests.

KEYWORDS: Ventral Hernias, Acute Pancteatitis, Incisional Hernia.**INTRODUCTION**

Acute Pancreatitis is a very common acute general surgical presentation. Many aetiological factors have been associated with acute pancreatitis, but it is most commonly attributed to gallstones and alcohol. Ventral hernias are infrequently associated with acute pancreatitis and there are few reports of this association in the medical literature.

CASE REPORT

An 83year old lady with a long history of a large incisional hernia that occurred following open cholecystectomy 20years ago presented with a 1day history of pain around the hernia and vomiting. The patient denied constipation and was passing flatus normally. She also denied recent alcohol consumption. Her past medical history included ischaemic heart disease, cardiac failure, hypothyroidism, and hypertension.

On examination, the patient's admission observations were within normal limits. On abdominal examination a large ventral incisional hernia overlying an upper midline laparotomy scar was detected. There was mild tenderness overlying the hernia but there was no clinical evidence of incarceration or strangulation.

Admission laboratory tests demonstrated an amylase of 1706 U/L, white cell count of 16.2 K/UL, alanine aminotransferase of 125 U/L, bilirubin of 26mmol/L and an alkaline phosphatase of 233 U/L, the remainder of her laboratory tests were unremarkable.

The patient was diagnosed with acute pancreatitis. She underwent a CT scan of her abdomen and pelvis to exclude a sub-acute intestinal obstruction secondary to the hernia. The CT scan confirmed the presence of acute pancreatitis but surprisingly a dilated common bile duct and a large ventral hernia containing the distal stomach, proximal duodenum, pancreas, and small bowel loops was also detected (figure 1).

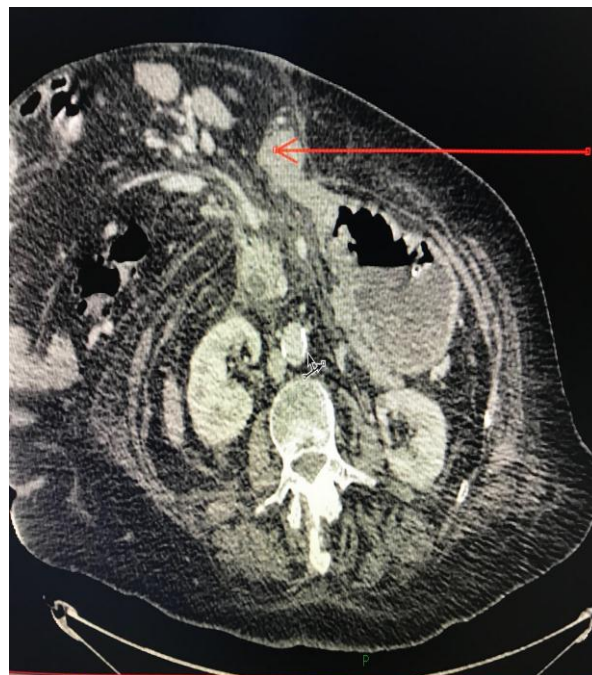

Figure 1: Axial CT image demonstrating a large incisional hernia with the distal stomach, duodenum (arrow) and part of the pancreas within the sac.

Due to the presence of deranged liver function tests a magnetic resonance cholangiopancreatography (MRCP) was performed to confirm or exclude the presence of common bile duct (CBD) calculi. The MRCP revealed a dilated CBD of 16mm with associated intra-hepatic ductal dilatation but no ductal calculi. The MRCP also demonstrated the ampulla and proximal duodenum within the incisional hernia leading to obstruction at the level of the duodenum (figure 2).

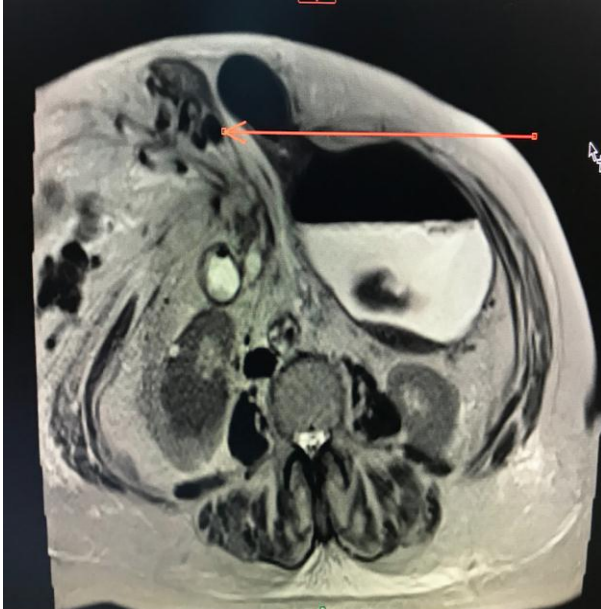


Figure 2: MRCP demonstrating a dilated common bile duct and the ampulla and proximal duodenum within the incisional hernia (red arrow).

Given this patient's age, significant medical comorbidities and frailty and following discussion of management options with the patient, a plan of conservative management was undertaken.

Following a brief period of conservative management the patient showed marked clinical improvement. In addition liver function tests and amylase normalised within 48hours of presentation. The patient was discharged home with no plans for either routine review or elective repair of the incisional hernia.

DISCUSSION

Incisional hernia is a recognised risk factor following abdominal surgery.^[1] The overall incidence of incisional hernia following laparotomy is 9.9%; this incidence is higher following midline incisions compared to transverse incisions.^[1] Risk factors for developing incisional hernias include obesity, diabetes, smoking, chronic obstructive pulmonary disease, connective tissue disorders, advanced age, immunosuppression, and wound infection.^[1] Complications due to incisional hernias include pain, bowel obstruction, incarceration and strangulation.^[2] In reviewing the medical literature only two cases have been described that describe ventral hernias complicated by acute pancreatitis. The first case

was a 50year old woman who presented with acute pancreatitis due to a longstanding incisional hernia containing a portion of the pancreatic head and the duodenum.^[3] The second case was reported by Lankisch *et al.* where a 70year old woman developed acute pancreatitis due to an incarcerated duodenal loop in a large ventral hernia.^[4] In this case it was postulated that acute pancreatitis was the result of retrograde reflux of duodenal contents induced by the incarceration of the duodenum in the hernia corresponding to an experimental model of acute pancreatitis called Pfeffer's closed duodenal loop model.^[4] This model postulated that acute haemorrhagic pancreatitis may be produced in dogs by creating a blind duodenal loop into which the pancreatic ducts drain but from which the bile has been excluded.^[5]

In the case that we describe however there was no evidence of incarceration on either the CT scan of the abdomen or in the MRCP. CBD and pancreatic duct obstruction at the level of the ampulla leading to pancreatic duct obstruction and/or bile reflux into the pancreatic duct was the most likely aetiology. This is supported by the fact that laboratory tests demonstrated derangement in the liver function tests and imaging demonstrated a dilated CBD in the absence of ductal calculi. A dilated CBD is commonly seen following cholecystectomy but the presence of abnormal liver function tests in the absence of ductal calculi makes the possibility of mechanical CBD obstruction more likely.

Regardless of its mechanism pancreatic duct obstruction can lead to proximal blockage of pancreatic secretions which in turn leads to a series of events that cause premature activation of trypsinogen and subsequently autodigestive injury to the parenchyma of the pancreas.^[6] Autodigestive injury initiates an inflammatory response within the pancreas. Biliopancreatic reflux has also been implicated in the generation of an inflammatory response within the pancreas due to the toxic effect of bile acids on the acinar cells.^[6]

We propose that pancreatic duct obstruction coupled with bile reflux was involved in the pathogenesis of acute pancreatitis in our case due to obstruction at the level of the ampulla impeding the secretions of both the common bile duct and the pancreatic duct.

We can deduce from this case that acute pancreatitis is potentially a serious albeit a rare complication of large ventral hernias. The risk of developing acute pancreatitis as a result of ventral hernias is unknown. We would advise consideration of early repair of large ventral hernias involving the duodenum and/or the pancreas to avoid development of acute pancreatitis providing the patient is fit for surgery to avoid the patient developing acute pancreatitis, a condition that is associated with a significant morbidity and mortality.^[6]

CONCLUSION

There is a clear association between pancreatitis and large ventral hernias involving the duodenum. Pancreatic duct and common bile duct obstruction is the most likely cause of acute pancreatitis in hernias involving the duodenum. Early surgical repair of large ventral hernias involving the duodenum and/or the pancreas need to be considered to prevent future development of acute pancreatitis.

GRANT

None.

CONFLICTS OF INTEREST

We the authors of this case report have no conflicts of interest to declare.

REFERENCES

1. Le Huu Nho R, Mege D, Ouaiissi M, Sielezneff I, Sastre B. Incidence and prevention of ventral incisional hernia. *Journal of Visceral Surgery*, 2012; 149(5): <https://www.sciencedirect.com> (accessed 25 August 2018).
2. Townsend CM, Beauchamp RD, Evers BM, Mattox KL. *Sabiston textbook of Surgery*, 20th ed. Canada: Elsevier Inc.; 2017.
3. Beblawi I, Caballero GA, Geenen JE. Acute pancreatitis complicating a huge ventral hernia: a case report. *Gastrointestinal Endoscopy*, 2000; 51(2): 216-217.
4. Lankisch PG, Petersen F, Brinkmann G. An enormous ventral (Epigastric) hernia as a cause of acute pancreatitis: Pfeffer's closed duodenal loop model in animal, first seen in a human. *Gastroenterology*, 2003; 124(3): 865-866.
5. McCutcheon AD. Reflux of duodenal contents in the pathogenesis of pancreatitis. *Gut*, 1964; 5(3): 260-265.
6. Lankisch PG, Apte M, Banks PA. Acute Pancreatitis. *The Lancet Clinic*, 2015; 386: www.thelancet.com (accessed 25/08/2018).