

**POST LUMBAR PUNCTURE INTRADURAL SPINAL ARACHNOID CYST
PRESENTING AS DORSAL MYELOPATHY WITH PARAPARESIS**

Dr. Omar Farooq and Dr. Mahpara Andrabi*

PG Scholar, Government Medical College Srinagar, Jammu and Kashmir.

***Corresponding Author: Dr. Mahpara Andrabi**

PG Scholar, Government Medical College Srinagar, Jammu and Kashmir.

Article Received on 24/09/2018

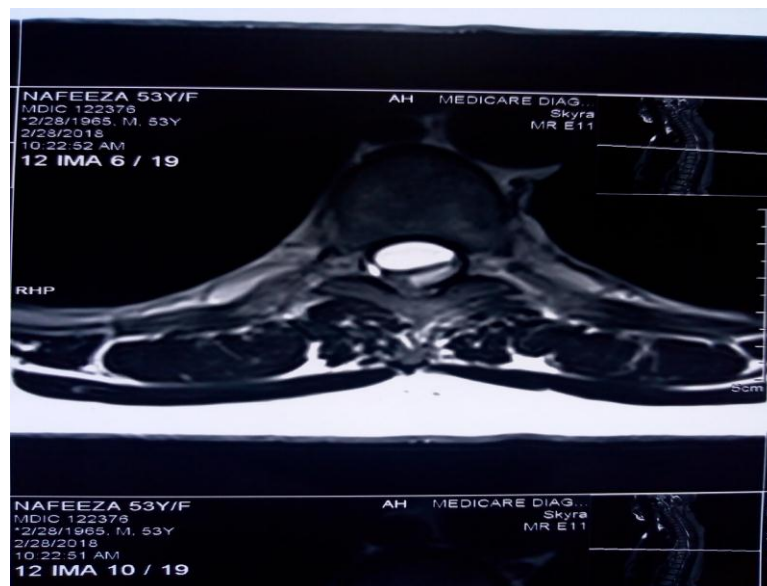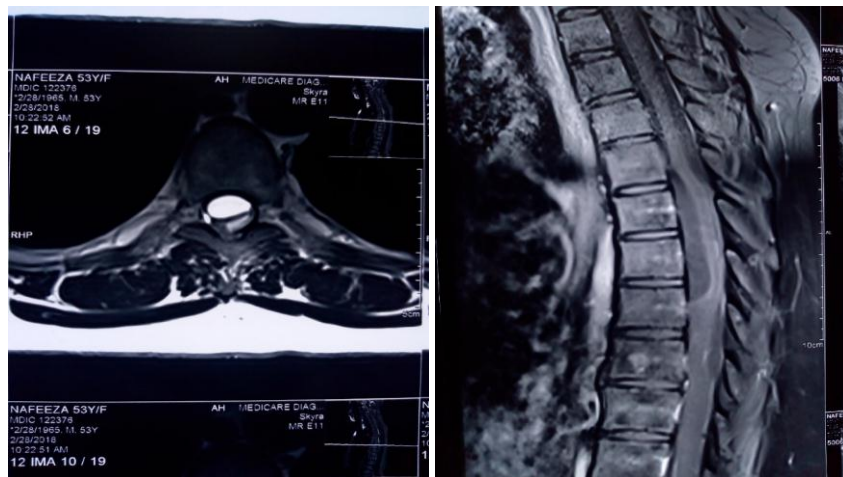
Article Revised on 15/10/2018

Article Accepted on 05/11/2018

35 year old female with insignificant past history apart from spinal anaesthesia for hysterectomy for menorrhagia 7 months back, was admitted for evaluation of dorsal myelopathy with spastic paraparesis of 6 months duration without bowel/bladder disturbances or sensory level, with normal sensations, upper limbs, cranial nerves, fundus and systemic examination.

Investigations revealed normal hemogram, KFTs, LFTs, Ultrasound abdomen and pelvis, ECG and chest Xray.

MRI revealed large intradural arachnoid cyst compressing the dorsolumbar spinal cord.



Arachnoid Cyst Pushing the Cord.

DISCUSSION

Acquired arachnoid cysts can be the result of spinal cord trauma, post-surgical arachnoiditis, meningeal infection and other insults that can cause inflammation and subarachnoid adhesions and even after lumbar puncture.

Most arachnoid cysts are found incidentally and can be managed conservatively. Intradural, non-neoplastic cysts compressing the spinal cord are rare lesions. These cysts should be considered in differential diagnoses of lesions causing myelopathy and/or a radicular pain syndrome. Microsurgical resection or generous fenestration in cysts with large craniocaudal extension effectively ameliorates patient's symptomatology. Treatment includes CP shunt placement, craniotomy or endoscopic shunt placement and stereotactic aspiration.