

**A LETHAL BENIGN METASTASIZING PLEOMORPHIC ADENOMA OF THE
PAROTID GLAND: A CASE REPORT AND REVIEW OF LITERATURE****Dr. Siham Ouguellit¹, Sarra Akla¹, Halima Abahssain¹, Sanae Sefiani², Jinan Abdullah³, Hamza Ettahri¹, Hind Mrabti¹ and Hassan Errihani¹**¹Department of Medical Oncology, National Institute of Oncology, Rabat 10000, Morocco.²Centre d'Anatomie Pathologique De l'Agdal (CAPA), Rabat, Morocco.³Department of Medical Oncology, Institut Gustave Roussy, Paris, France.***Corresponding Author: Dr. Siham Ouguellit**

Department of Medical Oncology, National Institute of Oncology, Rabat 10000, Morocco.

Email ID:

Article Received on 09/11/2018

Article Revised on 29/11/2018

Article Accepted on 19/12/2018

ABSTRACT

Benign Metastasizing Pleomorphic Adenoma of the parotid (BMPA) is an extremely rare entity. We report a case of a pleomorphic adenoma of the parotid in a 66-year-old woman who underwent several local surgeries before a fatal multiple metastatic relapse.

KEYWORDS: Parotid, adenoma, metastases.**INTRODUCTION**

Pleomorphic adenoma is a benign tumor of the salivary glands. This is the most common type of parotid tumor. Although these tumors are benign, they can undergo a malignant transformation years later to become either carcinoma ex-pleomorphic adenoma (CEPA) or carcinosarcoma.^[1] A much rarer phenomenon can also occur when a pleomorphic adenoma with completely benign histological characteristics is associated to locoregional or distant dissemination; this entity is termed Benign Metastasizing Pleomorphic Adenoma (BMPA). Most metastases occurs in patients who have undergone multiple surgeries with sometimes an interval of up to 52 years after treatment.^[2] The most frequent metastatic sites are bone, lung and lymph nodes.^[3] We report here a case of pleomorphic adenoma of the parotid gland with lung, pleural, bone and lymph node metastases.

CASE PRESENTATION

We present a case of 66-year-old woman with previous history of recurrent pleomorphic adenoma malignant disease. The patient presented initially in 2014 a slow growing mass in the left parotid gland, she underwent superficial left parotidectomy with facial nerve preservation with clear surgical margins. The histology confirmed a pleomorphic adenoma (PA). She presented two local recurrences 6 months and 1 year later. New surgery with mandibulotomy and deep parotidectomy was performed and confirmed a recurrent pleomorphic adenoma. The patient didn't receive any adjuvant treatment.

In January 2016, she was admitted to the hospital with dyspnea. Chest x-ray revealed multiple bilateral lung nodules. A contrast-enhanced computed tomography (CT) demonstrated multiple lung nodules, as well as pleural and lymph node metastases. A bone scan showed bony metastases; (Figure1). Pleural and lung biopsies were performed and no histologic characteristics of malignancy were seen in either specimen; therefore, a diagnosis of benign metastasizing pleomorphic adenoma was retained. (Figure.2)

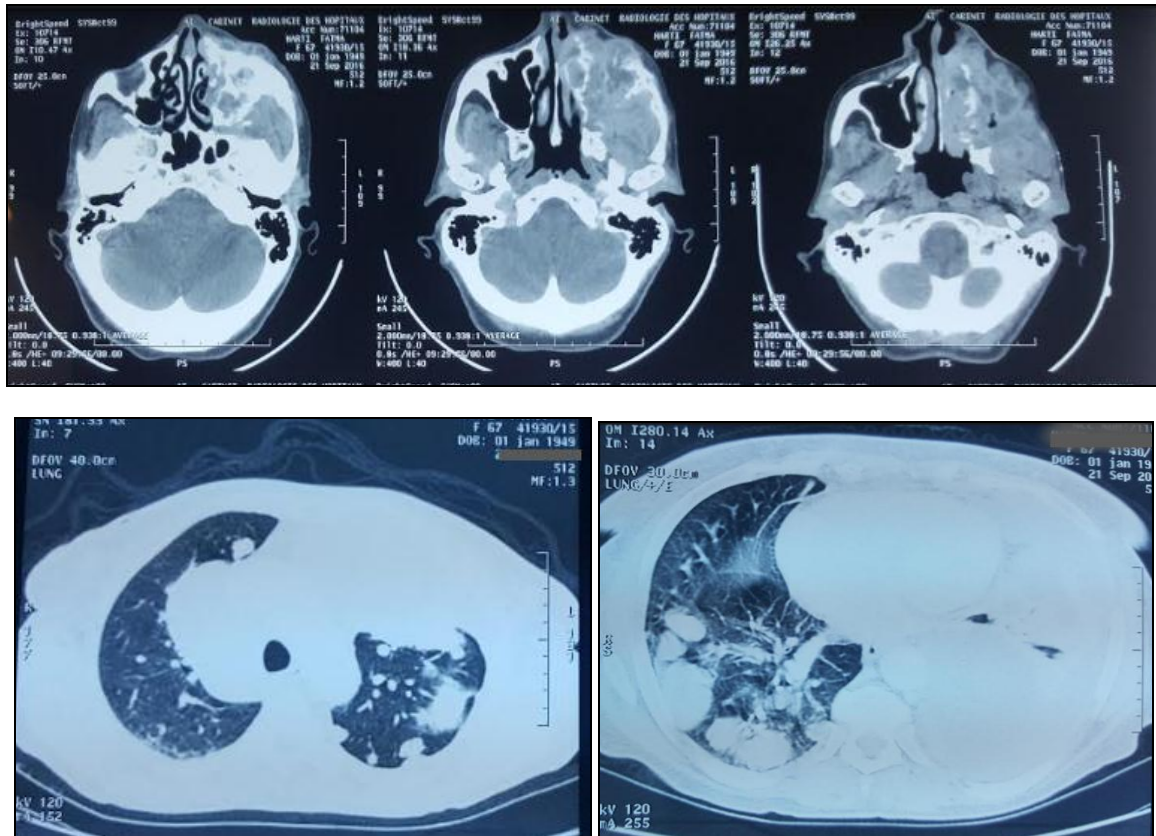
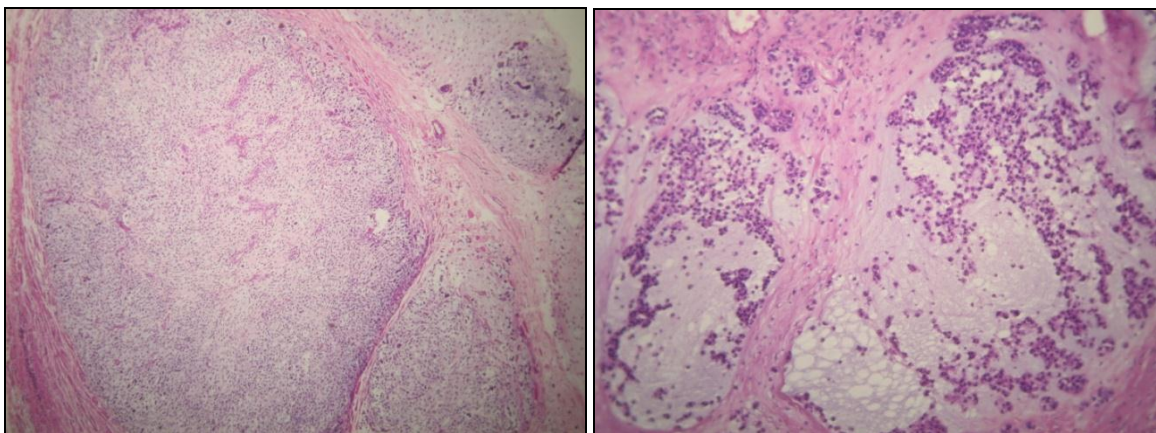
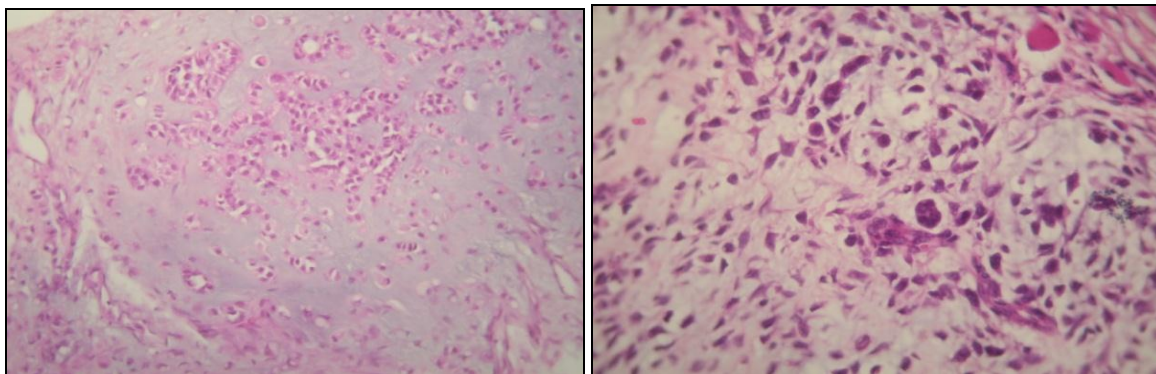


Fig. 1: Radiographic features of the local recurrence of the tumor (top row) and lung metastases (bottom row).



HES ×100 (hematoxylin, eosin, saffron) lobulated epithelial and conjunctival proliferation.



HES x 200: Tumoral epithelial proliferation on chondro-myxoid background

HES x 400: Cords of regular epithelial and myoepithelial cells in a hyaline stroma

Fig. 2.

Given the multiple metastatic sites and the Karnofsky Performance Status of 2, we opted for a monochemotherapy with capecitabine (2000 mg/m²/Day D1-14 of 21 day cycle)

After 3 cycles, the dyspnea totally disappeared. The patient received another 3 cycles, a full body CT scan performed after the 6th cycle demonstrated a progressive disease.

We decided to start a second line chemotherapy with weekly Paclitaxel (80mg/m²/week). The patient died after 2 cycles.

DISCUSSION

Benign Metastasizing Pleomorphic Adenoma (BMPA) is a very rare entity with about 60 cases reported in the literature to date. 81% of patients with BMPA had at least one episode of local recurrence prior to the first metastatic site; this local recurrence occurs in 90% of pleomorphic adenomas.^[4-5] The interval between the diagnosis of the primary tumor and the metastases is often long, 6 to 52 years.^[3]

Nouraei *et al.*^[6] found that patients presenting with metastases beyond 10 years after the diagnosis had a better prognosis compared to those presenting with metastases within 10 years.

Histologically, Benign Metastasizing Pleomorphic Adenoma is considered by the World Health Organisation as a subtype of pleomorphic adenoma. It presents the same histological characteristics as the pleomorphic adenoma with the association of two components: an epithelial component, consisting of benign ductal structures and myoepithelial cells, and an amelanotic mesenchymal appearing component, showing fibrous, chondroid or myxoid features.^[7-8]

To date, there are no morphologic features that can predict which of the locally recurrent pleomorphic adenomas has the potential to metastasize.^[9] According to some authors, the metastatic forms would have a higher mitotic index, but this hypothesis was not retained.^[10]

In case of recurrent pleomorphic adenoma with suspicion of distant metastases, the computerized axial tomography (CT), magnetic resonance imaging (MRI) or PET scan are excellent imaging tools to determine possible malignant dissemination.^[8]

Rehnan *et al.* described bone as the most common metastatic site (45%) followed by the head and neck (43%) and lung 36%, other metastatic sites have also been reported: liver, kidney, skin, central nervous system, and retroperitoneal regions.^[3]

The mechanism of metastases is not yet clear. Some authors believe that incomplete surgery or surgical

manipulations would promote intravascular spread of tumor cells.^[9-11]

The appropriate initial management of patients with pleomorphic adenoma may prevent the occurrence of distant metastases by realizing a total conservative parotidectomy with adequate margins and preservation of the facial nerve, this surgery has reduced recurrence rates to 5%^[8-12]

Several studies have investigated the benefits of postoperative radiotherapy after parotidectomy for pleomorphic adenoma. Its value has not been demonstrated except in case of incomplete surgery or multiple local recurrences.^[13-14]

For solitary metastasis, surgery should remain the treatment of choice whenever possible.^[10-12] Nouraei S, *et al.* reported a significant benefit in five-year disease-free survivals of 58% versus 50% in the absence of surgical treatment.^[6]

Due to the limited number of reported cases, the role of chemotherapy and radiotherapy in non metastatic setting remains uncertain^[10-12]

CONCLUSION

Metastasizing pleomorphic adenoma is a rare and controversial entity; it's a histologically benign but clinically malignant manifestation of pleomorphic adenoma. The surgical removal of the metastatic focus improves the survival rate and decrease tumor recurrence, which itself may lead to multiple surgeries and more extensive therapies.

ACKNOWLEDGEMENTS

None.

Conflicts of Interest

The authors have no conflicts of interest to declare.

REFERENCES

1. Stennert E, Guntinas-Lichius O, Klussmann JP, Arnold G. Histopathology of pleomorphic adenoma in the parotid gland: a prospective unselected series of 100 cases. *Laryngoscope*, 2001; 111(12): 2195-200.
2. B. M. Wenig, C. L. Hitchcock, G. L. Ellis and D. R. Gnepp, "Metastasizing Mixed Tumor of Salivary Gland: A Clinicopathologic and Flow Cytometric Analysis," *American Journal of Surgical Pathology*, 1992; 16(9): 845-858.
3. Rehnan A, *et al.* Long, Äêterm follow, Äêup of over 1000 patients with salivary gland tumours treated in a single centre. *British journal of surgery*. 1996; 83(12): 1750-1754.
4. Rodriguez-Fernandez J, Mateos-Micas M, Martinez-Tello FJ, Berjon J, Montalvo JJ, Forteza-Gonzalez G, *et al.* Metastatic benign pleomorphic adenoma.

- Report of a case and review of the literature. *Med Oral Patol Oral Cir Bucal*. 2008; 13(3): E193–6.
5. Oh YS, Eisele DW. *Head and Neck Surgery--otolaryngology - Volume 1*. 4th ed Philadelphia: Lippincott Williams & Wilkins, 2006.
 6. Nouraei S, *et al.* Metastasizing pleomorphic salivary adenoma. *Archives of Otolaryngology, Head & Neck Surgery*. 2006; 132(7): 788-793.
 7. Seifert G1, Brocheriou C, Cardesa A, Eveson JW. WHO International Histological Classification of Tumours. Tentative Histological Classification of Salivary Gland Tumours. *Pathol Res Pract*, 1990. 186(5): 555-81.
 8. McGarry *et al.* Metastatic pleomorphic adenoma to the supraspinatus muscle: a case report and review of a rare aggressive clinical entity. *Radiology Case*. 2015 Oct; 9(10): 1-8.
 9. Manucha V, OB Ioffe. Metastasizing pleomorphic adenoma of the salivary gland. *Archives of pathology & laboratory medicine*, 2008; 132(9): 1445-1447. PMID: 18788859.
 10. Moonim M. A unique case of benign pleomorphic adenoma metastasizing to the thyroid gland and liver *Case Reports in Clinical Pathology*, 2015; 2(4).
 11. Wenig BM, *et al.* Metastasizing mixed tumor of salivary glands: a clinicopathologic and flow cytometric analysis. *The American journal of surgical pathology*, 1992; 16(9): 845-848.
 12. Giuditta Mannelli, Unusual Metastases from a Pleomorphic Adenoma of the Parotid Gland: A Case and Literature's Review *International Journal of Otolaryngology and Head & Neck Surgery*, 2013; 2: 232-235.
 13. Witt RL, *et al.* Etiology and management of recurrent parotid pleomorphic adenoma. *The Laryngoscope*, 2014.
 14. Robertson B, *et al.* Pleomorphic adenomas: Post-operative radiotherapy is unnecessary following primary incomplete excision: A retrospective review. *Journal of Plastic, Reconstructive & Aesthetic Surgery*, 2014.