

## INVERTED PAPILOMA OF THE NASAL CAVITY - A CASE REPORT

Dr. Nitika Kumari\* and Dr. G Anushuya

1<sup>st</sup> Year Postgraduate, Department of Pathology, SBMCH, Chennai, Tamil Nadu.

\*Corresponding Author: Dr. Nitika Kumari

1<sup>st</sup> Year Postgraduate, Department of Pathology, SBMCH, Chennai, Tamil Nadu.

Article Received on 25/11/2018

Article Revised on 18/12/2018

Article Accepted on 09/01/2019

### ABSTRACT

Inverted papilloma is a rare, benign sinonasal tumor. Its etiology is the most likely related to HPV infection. Inverted papilloma originates from the ciliated respiratory epithelium, typically from the lateral nasal wall. The tumor is characterized by endophytic growth inwards the stroma with adjacent tissues destruction. The clinical symptoms are non-specific, such as unilateral obstruction of the nasal duct, rhinorrhoea, epistaxis and anosmia. Inverted papilloma has a tendency to recurrence with incomplete resection and a potential to malignant transformation to squamous cell carcinoma. This paper presents a female patient with clinical symptoms of nose block, headache and anosmia.

**KEYWORDS:** Benign tumors; inverted papilloma.

### INTRODUCTION

Inverted papilloma is a benign epithelial growth extending into the underlying stroma of the nasal cavity and paranasal sinus. The tumor is well known for its invasiveness, tendency to recur and association with malignancy. In 1854, Ward first documented the occurrence of inverted papilloma in the sinonasal cavity. However, in 1935, Reingertz histologically described the nature of the tumor and noted its classic inverted nature in underlying connective tissue stroma. In 1971, Hymans reviewed several cases of this tumor and subdivided sinonasal papilloma into inverted, fungiform and cylindrical cell types. It is a rare benign tumor with incidence rate of 0.6 cases/100,000 people/year. It comprises 0.5–4% of all primary nasal tumors. It usually arises from the lateral nasal wall, in the middle meatus, often extending to the ethmoid and maxillary sinuses. In advance cases, extension into all of the ipsilateral peripheral nervous system may occur whereas intracranial growth and dural penetration are rare. The pathogenesis of this lesion remains unclear although allergy, chronic sinusitis and viral infections have been suggested as possible causes. Positive diagnosis is based on clinical examination, nasal endoscopy and imaging, as well as histopathological findings.

### CASE REPORT

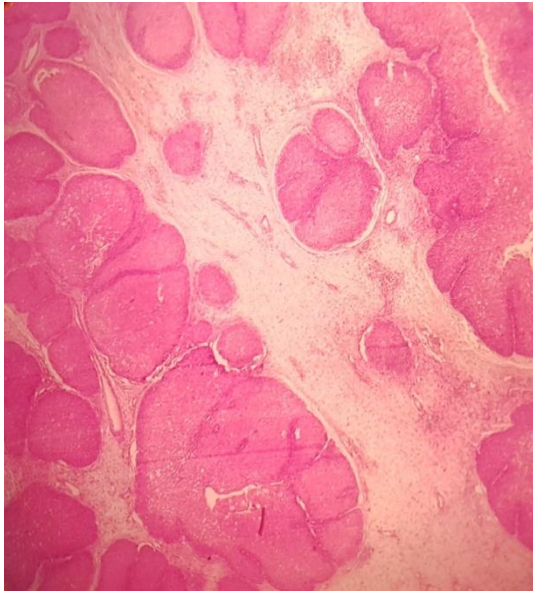
A 50 years old female patient presented with complaints of right side nasal block since 8 months. It was associated with headache and anosmia. Nasal mass was excised and excision biopsy specimen was sent for HPE.

#### Gross

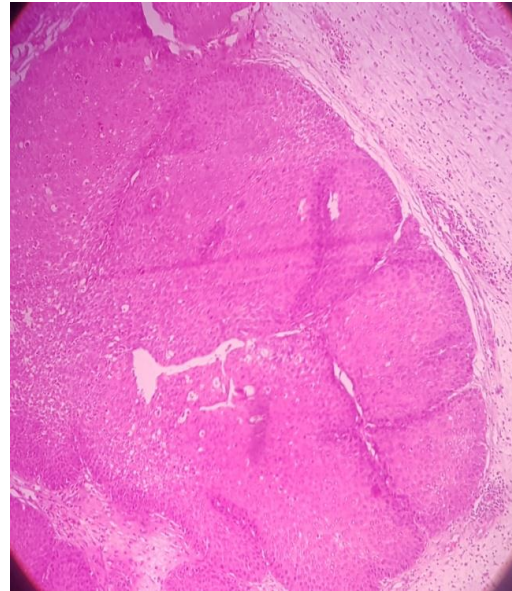
Multiple soft tissue fragments, largest measuring 2.5x1.5x1 cm and smallest measuring 0.5 cm in diameter, grey-white in color, irregular in shape and firm in consistency.

#### Microscopy

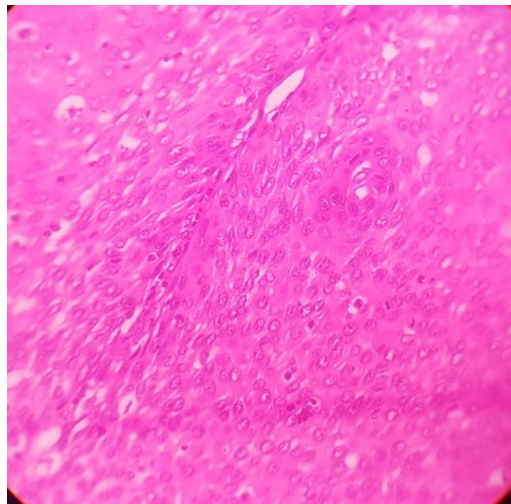
On histological examination, the hematoxylin and eosin stained section shows lesion lined by stratified squamous epithelium with endophytic invaginating nests of squamous epithelium with peripheral palisading. The nests are separate by fibrous stroma, infiltrated by acute and chronic inflammatory cells. Also seen are neutrophils, micro abscess within the squamous nests. The cellular growth also shows mucin and focally lined by respiratory epithelium. Cellular islands also surround bony spicules. No evidence of necrosis.



Scanner view of the section shows an endophytic or inverted growth pattern of squamous epithelial growing downward into the underlying connective tissue stroma to form large clefts and islands.



Low power view of inverted papillomas.



High power view of inverted papilloma.

## DISCUSSION

Inverted papilloma (synonym: Ringertz tumor, transitional cell papilloma, fungiform papilloma, cylindrical cell papilloma, schneiderian cell papilloma, epithelial papilloma, papillary sinusitis, soft papilloma and sinonasal-type papillomas) can be defined as a group of benign neoplasm arising from the sinonasal (Schneiderian) mucosa and is composed of squamous or columnar epithelial proliferation with associated mucous cells. The ectoderminally derived lining of the sinonasal tract, termed as the schneiderian membrane, may give rise to three morphologically distinct benign papillomas (Schneiderian papillomas).

- Inverted
- Oncocytic (cylindrical or columnar cells)
- Fungiform (exophytic, septal).

Collectively, schneiderian papillomas represent <5% of all sinonasal tract tumors. The literature indicates that among sinonasal-type papillomas, the septal papilloma is the most common; however, practical experience indicates that the inverted type is the most common subtype and the oncocytic type is the least common. In general, sinonasal-type papillomas occur over a wide age range but are rare in children; however, septal papillomas tend to occur in a younger age group. Inverted papillomas occur along the lateral nasal wall (middle turbinate or ethmoid recesses), with secondary extension into the paranasal sinuses. They may originate in paranasal sinus with/without involving nasal cavity. Typically, the schneiderian papillomas are unilateral; bilateral papillomas may also occur. In the presence of bilaterality, clinical evaluation to exclude the possibility of extension from unilateral disease should be undertaken. Symptoms vary according to the site of

occurrence and include airway obstruction, epistaxis and a symptomatic mass or pain. Schneiderian papillomas may occur simultaneously with nasal inflammatory polyps.

The viral etiology has been suggested in few studies and inverted papillomas are reported to be positive for human papillomavirus (HPV) on *in situ* hybridization and/or polymerase chain reaction. The HPV 6, HPV 11, HPV 16, HPV 18 and Epstein–Barr virus have been isolated. Whether there is a cause and effect between the presence of HPV and the development of inverted papillomas remains to be determined.

Histologically, inverted papillomas have an endophytic or inverted growth pattern consisting of markedly thickened squamous epithelial proliferation growing downward into the underlying connective tissue stroma to form large clefts, ribbons and islands. The epithelium varies in cellularity and is composed of squamous, transitional and columnar cells (all 3 may be present in a given lesion) with admixed mucocytes (goblet cells) and intraepithelial mucin microcysts. A mixed chronic inflammatory cell infiltrate is characteristically seen within all layers of the surface epithelium. The cells are generally bland in appearance with uniform nuclei and no piling up; however, pleomorphism and cytoplasmic atypia may be present. The epithelial component may demonstrate extensive clear cell features indicative of abundant glycogen content. Mitotic figures may be seen in the basal and parabasal layers, but atypical mitotic figures are not seen. Surface keratinization may be present. The stromal components vary from myxoid to fibrous, with admixed chronic inflammatory cells and variable vascularity. Intraepithelial mucocytes show intra cytoplasmic mucin positive material, which is Mucicarmine positive and diastase – resistant, PAS – positive.

Differential diagnosis includes sinonasal inflammatory polyps, nonkeratinizing respiratory carcinoma and verrucous carcinoma. Sinonasal inflammatory polyps are clinically similar but histopathologically epithelial alterations are seen in inverted papillomas and not in the inflammatory polyps. Sometimes nonkeratinizing respiratory carcinoma mimics inverted papillomas and then they can be differentiated by the presence of dysplastic features in carcinoma. In verrucous carcinoma, characteristically, cleft-like spaces lined by a thick layer of parakeratin extending from the surface deeply into the lesion which is the hallmark of verrucous carcinoma, is seen and is absent in inverted papilloma. The potential for recurrence and malignant transformation, scholarly literature recommends using endoscopic treatment in case of limited invasion in the nasal cavity, ethmoidal cells and partially at the level of maxillary, sphenoidal and frontal sinuses. The rate of recurrence varies between 0-27%.

## CONCLUSION

The inverted papilloma comprises only 0.5–4% of all primary nasal tumor, one can suspect inverted papilloma if mass in nasal cavity seems to be arising from lateral nasal wall, with involvement of at least 1 paranasal sinus, presenting in male patient of the fifth and sixth decade of life. Common symptoms include unilateral nasal obstruction, epistaxis and sinusitis with nasal discharge. Although the intent of surgical procedures were curative, recurrence rates of 40–80% were unacceptably high. Open approaches such as the lateral rhinotomy and midfacial degloving procedures allowed for increased tumor visualization and more complete resection including maxillectomy, which minimizes the recurrence rates.

## REFERENCES

1. Lawson W, Ho BT, Shaari CM, Biller HF. Inverted papilloma: a report of 112 cases. *The Laryngoscope*, 1995 Mar; 105(3): 282-8.
2. Pasquini E, Sciarretta V, Farneti G, Modugno GC, Ceroni AR. Inverted papilloma: report of 89 cases. *American journal of otolaryngology*, 2004 May 1; 25(3): 178-85.
3. Mirza S, Bradley PJ, Acharya A, Stacey M, Jones NS. Sinonasal inverted papillomas: recurrence, and synchronous and metachronous malignancy. *The Journal of Laryngology & Otology*, 2007 Sep; 121(9): 857-64.
4. Khandekar S, Dive A, Mishra R, Upadhyaya N. Sinonasal inverted papilloma: A case report and mini review of histopathological features. *Journal of oral and maxillofacial pathology: JOMFP*, 2015 Sep; 19(3): 405.