

**CORRELATION OF ABDOMINAL SONOGRAPHY AND COMPUTED TOMOGRAPHY  
WITH OPERATIVE FINDINGS IN SURGICAL PATIENTS**Dr. Ajinkya N. Puppal<sup>\*1</sup>, Dr. Ajinkya N. Puppal<sup>2</sup> and Dr. Shrishail Adke<sup>3</sup>

Mumbai, Maharashtra, India.

**\*Corresponding Author: Dr Ajinkya N. Puppal**

Mumbai, Maharashtra, India.

Article Received on 20/12/2018

Article Revised on 10/01/2019

Article Accepted on 01/02/2019

**ABSTRACT**

**Background:** The purpose of this study is to know the role of preoperative evaluation by USG and CT in managing surgical patients. The patients with acute abdominal pain may provide many problems in diagnosis and decision making, whether operative intervention is required. **Method:** The study was carried out in patients of Department of General Surgery in Krishna Hospital and Medical Research Centre, Karad in 2 years' time period. We evaluated 200 patients with USG and 50 with CT scan. **Results:** We evaluated 200 patients with USG and the diagnosis was correct in 135. In cases of appendicitis and blunt trauma abdomen, USG has too low sensitivity. The diagnostic accuracy for Gall bladder diseases is high. **Conclusion:** Though USG and CT are helpful to the surgeon in managing the patients, clinical assessment is invaluable.

**KEYWORDS:** Operative findings, USG, CT.**INTRODUCTION**

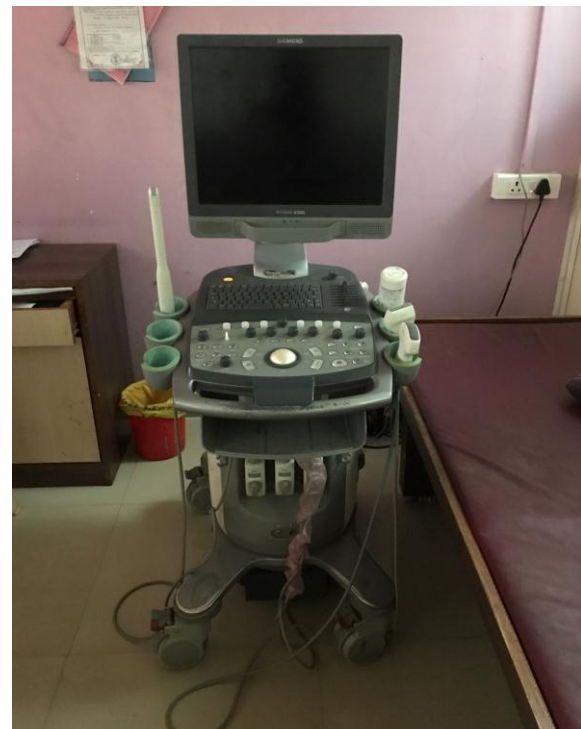Abdominal USG and CT scan are done for acute and chronic abdominal conditions, TNM staging of malignant condition & other Urological conditions. Diagnosing a patient with acute abdominal pain is a challenge for the surgeon. It is crucial to decide whether surgical intervention is required or not. Ultrasound and CT scan are being used increasingly as a diagnostic tool. All blunt trauma patients with possibility of intra-abdominal injury are screened with USG.

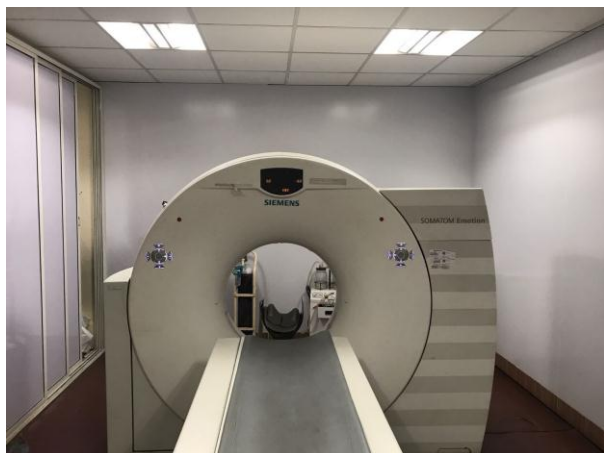Grey scaling in USG gives more precise anatomical details, as well as more information about the texture of various organs based on their elasticity and density. This in turn leads to improved differential diagnosis of abdominal lumps.

The main disadvantage is that USG is mostly operator dependent. So the accuracy depends on the expertise of the sonologist.

Computed Tomography was developed by Hounsfield and Ambrose for the study of intracranial disease. Recently, CT is being used to diagnose intra thoracic, intra-abdominal and retro peritoneal pathologies as well.

The main aim of this study is to determine the role of pre-operative USG and CT in managing surgical patients.

**Ultrasound Machine**



**Computed Tomography Machine**

## METHODS

**Ethical statement:** The study met the standards outlined in the Declaration of Helsinki and Good Epidemiological Practices. The study did not change or modify laboratory or clinical practices of each Centre and differences of practices were kept as they are. The data collection was anonymous and identifiable patient information was not submitted.

Individual researchers were responsible for complying with local ethical standards and hospital registration of the study.

**Study population:** The present study was carried out in patients of the Department of General Surgery in Krishna Hospital and Medical Research Centre, Karad for time period of 2 years. We evaluated a total of 250 patients. The use of USG was studied in 200 patients and Computed Tomography in 50 patients.

**Patient selection:** The patients whose preoperative USG or CT is done are selected. Then after operation USG & CT findings are correlated with operative findings.

**Preparation of patient:** For routine ultrasonography and computed tomography, patients were kept NBM for 4 hours with proper bowel preparation. USG was done with full bladder. During emergency, USG was done without this preparation.

**USG technique:** Ultrasonography is done in supine, prone or right or left lateral position depending on the organ to be examined. Coupling jelly was used to provide intimate skin contact.

**CT technique:** CT is done by Siemens 16 slice CT machine in supine position after achieving proper immobilization.

Slice thickness- 1.5mm & 5mm.

I.V. contrast: Non ionic iodinated isomolar contrast.

## OBSERVATION

Total 250 patients for USG and CT were studied.

**Table 1: Sex Ratio.**

Sex	No. of patients	Percentage
Male	175	70
Female	75	30

**Table 2: Age incidence.**

Age group	No of patients	Percentage
0-10	39	15.6
11-20	42	16.8
21-30	38	15.2
31-40	25	10
41-50	35	14
51-60	24	9.6
61-70	20	8
71-80	15	6
81-90	12	4.8

**Table 3: Type of patients for USG.**

USG evaluation	Number of patients
Appendicitis	58
Cholelithiasis	27
Intestinal Obstruction	19
Blunt trauma abdomen	35
Urological	45
Abdominal lumps	16
<b>Total</b>	<b>200</b>

**Table 4: Diagnostic accuracy of USG.**

### A.) Appendicitis

	Accurate	Inaccurate	Total
Appendicitis	40	18	58

Diagnostic accuracy was 68.96%

### B.) Cholelithiasis

	Accurate	Inaccurate	Total
Cholelithiasis	20	7	27

Diagnostic accuracy was 74.07%

### C.) Intestinal obstruction

	Accurate	Inaccurate	Total
Intestinal obstruction	12	7	19

Diagnostic accuracy is 63.15%

### D.) Blunt trauma abdomen

	Accurate	Inaccurate	Total
Blunt trauma abdomen	21	14	35

Diagnostic accuracy was 60%.

**E.) Urological**

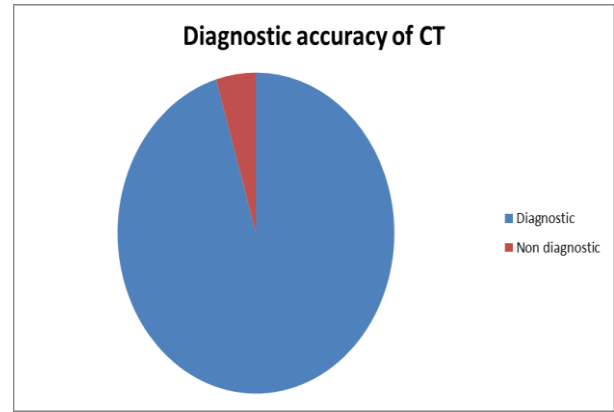
	Accurate	Inaccurate	Total
Total	31	14	45

Diagnostic accuracy was 68.88%

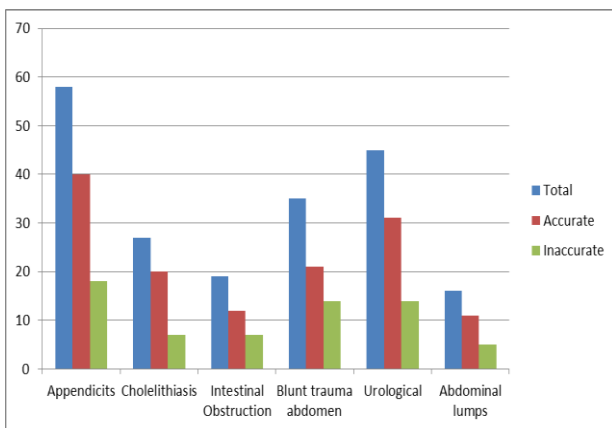
**F.) Abdominal Lumps**

	Accurate	Inaccurate	Total
Abdominal lumps	11	5	16

Diagnostic accuracy was 68.75%



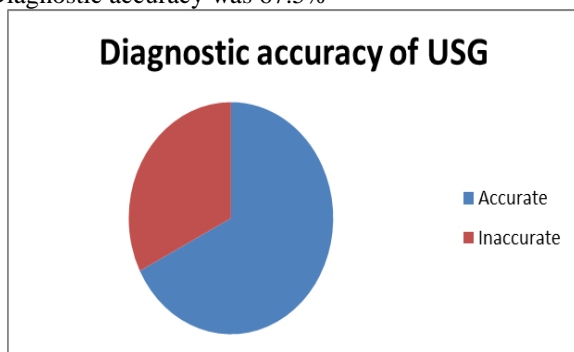
**Table 5: Correlation between USG findings and operative findings.**



**Table 6: Diagnostic accuracy for USG.**

Diagnostic	Non Diagnostic	Total
135	65	200

Diagnostic accuracy was 67.5%



**Table 7: Diagnostic accuracy for CT.**

Diagnostic	Non diagnostic	Total
41	9	50

Diagnostic accuracy was 82%

**DISCUSSION**

USG and CT are the most frequently means in evaluation of surgical patients.

The study included a total of 250 patients, 200 of which underwent USG and 50 underwent CT.

**Appendicitis**

- Abu Yousef, 1987 reported accuracy of 90% in his study of 68 patients.<sup>[1]</sup>
- R. Brooke Jeffrey, 1988 reported accuracy of 93.9% in 250 patients.<sup>[2]</sup>
- Vignault, 1990 reported accuracy of 91% in 70 patients.<sup>[4]</sup>

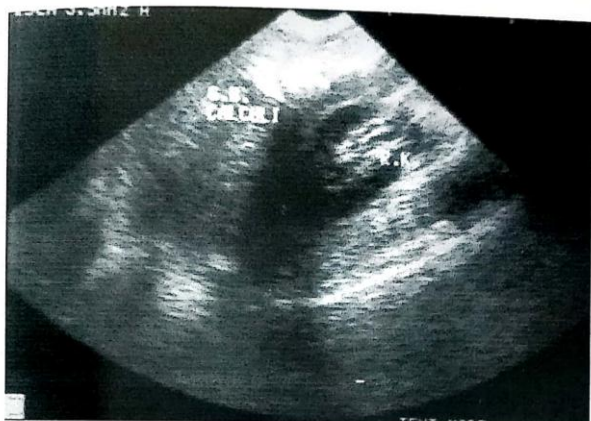The diagnostic accuracy in our study is 68.96%. Out of 58 cases, USG was diagnostic in 40. The appendix was not visualized in 18 patients. The criteria to diagnose appendicitis are maximal outer appendiceal diameter of 6mm or more lack of compressibility, lack of peristalsis and demonstration of blind tip. Free fluid is found frequently near an inflamed appendix but is not specific.

Perforated appendicitis is seen with periappendicular inflammation. However the results of USG in perforated appendicitis are not convincing.<sup>[4]</sup> This might be due to loss of sonomorphological characteristics of appendix, improper visualization due to atonic bowel loops or reflex rigidity of abdominal walls not allowing graded compressions.

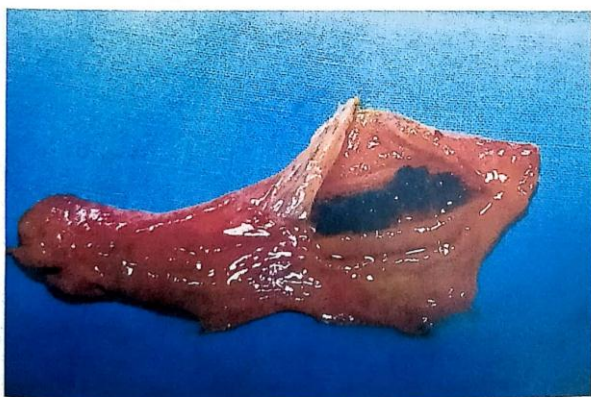**Cholelithiasis**

Goldberg and Harris, 1974 reported 72% true positive and 59% false negative reports in identifying gallstones.<sup>[5]</sup>

Barhim and Lutz et al, 1976 demonstrated 92% accuracy in identifying gallstones.<sup>[6]</sup>



USG – Gall stones



Cholelithiasis

Sherman *et al.*, 1980 studied 20 cases and was accurate in all of them.<sup>[7]</sup>

We studied a total of 27 patients and were accurate in 20 cases.

USG signs of acute cholecystitis are wall thickening of more than 4mm, hypoechogenic thickening of tissues surrounding gall bladder and a hypoechogenic band of pericholecystic fluid. Localised pain while performing USG, called sonographically guided Murphy's sign is supportive of diagnosis.

Normally, the Common bile duct measures 2-6mm and may measure upto 10mm in elderly and post cholecystectomy.<sup>[8]</sup> Values above 10mm suggest biliary obstruction. Extra hepatic bile duct dilation is suspected with CBD diameter more than 8mm in a previously healthy person and 10mm post-surgery involving biliary tract.

USG is considered the diagnostic modality of choice in acute cholecystitis.<sup>[9]</sup>

### Abdominal Lumps

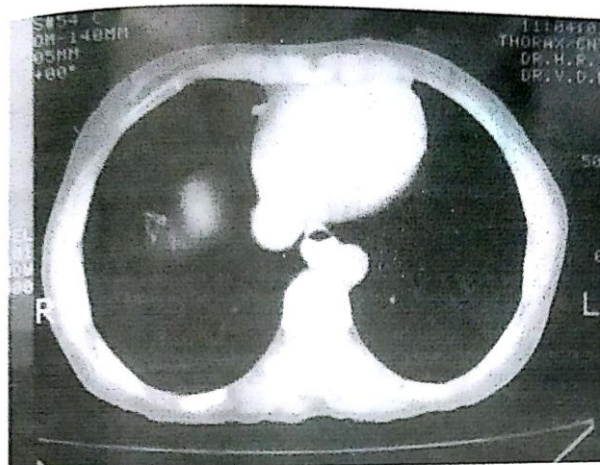
- USG in abdominal lumps are useful in confirming presence or absence of lump.
- Determining organ of origin.
- Extent of spread.
- To predict tumor type.

Although CT is more accurate in diagnosing abdominal lumps, it is expensive. USG is a cheaper and more readily available option.

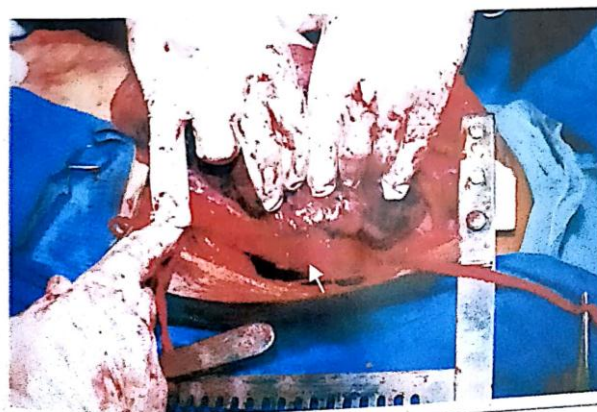Filly and Freimans, 190 studied 37 cases and detected pancreatic edema, pseudocyst and Ca pancreas.<sup>[10]</sup>

Duncan *et al.*, 1976 diagnosed pseudocyst of pancreas in 23 out of 38 cases.<sup>[11]</sup>

We studied 16 cases and USG was diagnostic in 11 of them. In one case, ultrasound diagnosis was a mass arising from Caecum, but on exploration it was found to be a mass arising from mesocolon and terminal ileum.



CT – loss of fat planes between oesophageal growth and aorta



Aorta free from oesophageal growth infiltration

→ Oesophageal growth

### Blunt trauma abdomen

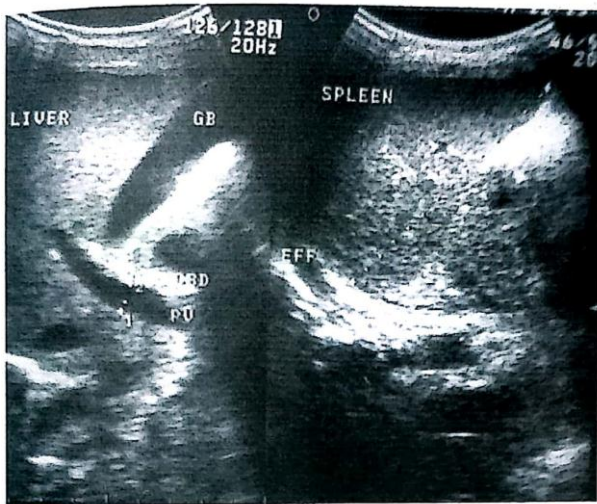Abu zidem, 1996 studied 53 cases of blunt trauma abdomen and stated that USG was 85% sensitive, 100% specific and 96% accurate.<sup>[12]</sup>

Amongst liver and splenic injuries, subcapsular haematoma, intrasplenic haematoma, contusion, laceration or rupture can be diagnosed on USG.

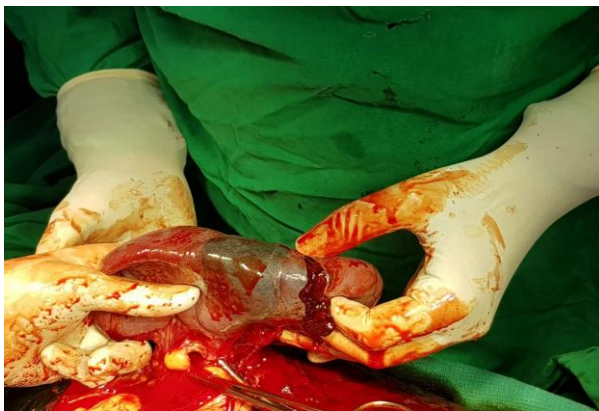By accurately estimating the volume and rate of intraperitoneal haemorrhage, USG plays a vital role in cases of blunt trauma abdomen.

But in our study, USG is not accurate enough and often underestimates the organ injury.

We studied 35 cases and were able to diagnose 21 cases with an accuracy of 60%.



USG - Spleen normal in size and echotexture



Splenic Laceration

### Urological

Renal USG is useful in diagnosing congenital anomalies, renal cysts, renal tumors, renal trauma, obstructive uropathy and pyelonephritis.

Renal cyst is recognized by a well demarcated, rounded, completely echo free mass.

USG is crucial in showing the spread of malignancy, beyond the renal capsule, into adjacent organs, retroperitoneal structures, renal veins and IVC.<sup>[13]</sup>

Renal calculi and hydronephrosis, hydroureter are best demonstrated by USG.<sup>[14]</sup>

We studied 45 cases and our diagnosis was correct in 31 cases with accuracy of 68.88%.

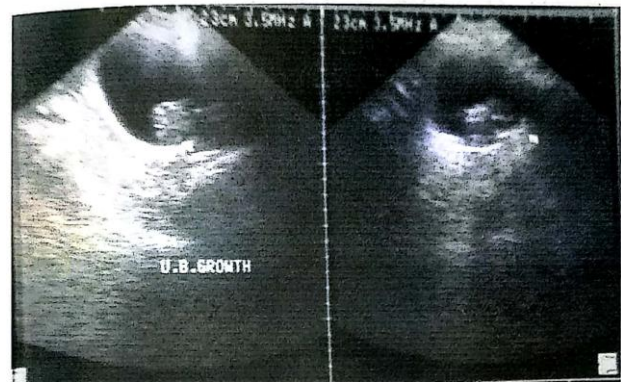### Intestinal obstruction

We studied 19 cases of intestinal obstruction and were able to diagnose correctly 12 cases with an accuracy of 63.15%.

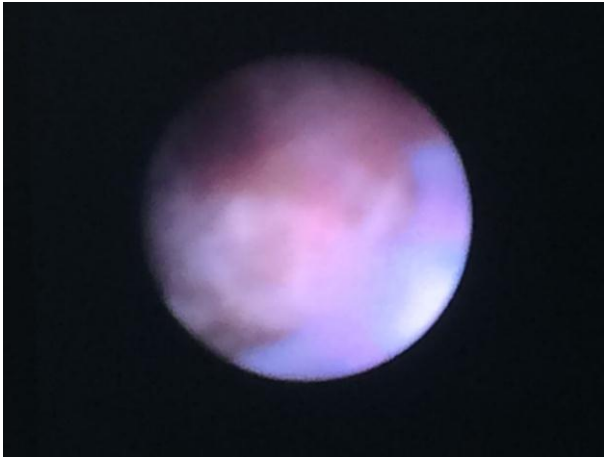The USG findings of obstructed bowel include dilated fluid-filled bowel loops with hyperechoic spots of gas moving within the fluid. The diameter of small bowel is 3-4 cm and that of large bowel is 4-5 cm. Those dilated loops may show thickened wall, thickened vavulae conniventes and increased to and fro motion of bowel contents.

In our CT study, 50 patients were included of which we were able to diagnose 41 cases with an accuracy of 82%.

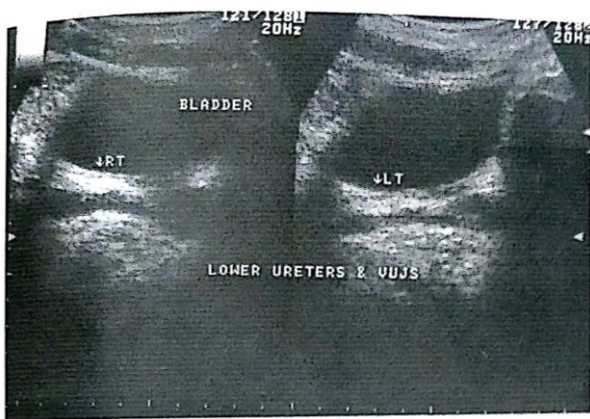
CT scan is an invaluable tool in diagnosing abdominal conditions especially where USG fails. It is a highly accurate mode of investigation. However in one case, CT showed a distinct fat plane between gastric cancer and pancreas, but on exploration, the tumor had invaded the pancreas. In one it showed spread of esophageal tumor into the aorta, but on exploration the tumor was found to be resectable.



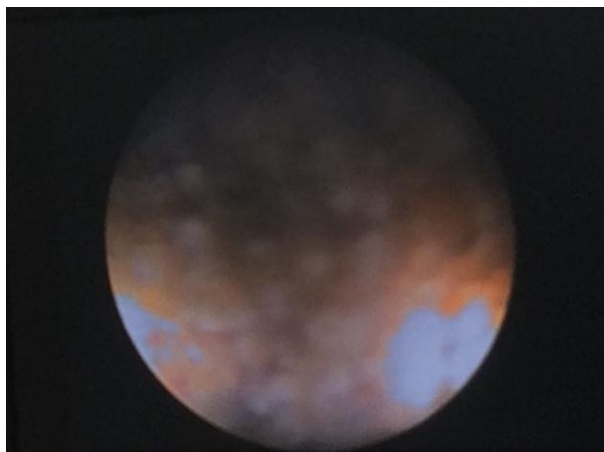
USG - U.B. growth left lateral wall



Cystoscopy -Cystitis



USG – lower ureters normal



Left ureteric Calculus

## CONCLUSION

Though USG and CT are helpful in aiding in management of surgical abdomen, clinical assessment is invaluable.

USG being easily available, inexpensive, safer, non-invasive, it is used as an initial mode of investigation.

The two main drawbacks of USG are operator dependability and the type of machine used. CT succeeds where USG fails, but is however expensive and not easily available.

## REFERENCES

1. Abu Yousef M, Bleacher J, Maher J.W, et al: resolution sonography of acute appendicitis. *AJR*, 149: 53-58; 19833369997.
2. Jeffrey R. B JR laing, FC Townsend R.R; Acute appendicitis: sonography criteria based on 250 cases. *Radiology*, 1988; 167: 327-333.
3. Vignault F, FilatrautD, Brandt M.L, et al: acute appendicitis in children: evaluation with US radiology, 1990; 176: 501-504.
4. Zielke A, Malewski U, Linder et al: ultrasound in acute appendicitis for general surgeon: option or necessary? *Chirurg*, 1991; 62: 742-749.
5. Goldbery B.B, Harris K.A; Ultrasonic and radiographic cholecystography. *Radiology*, 1974; 111; 405.
6. Barhim lutz et al: ultrasonic examination of gall bladder. *Radiology*, 1973; 110: 643.
7. Sherman M, Ralls P, W Halls J.I.U: cholangiography and sonography in acute cholecystitis *Am J Roentgenology*, 1980; 135: 313.
8. Graham M.E, Cooperberg P.L, Gohem MM: the size of normal common hepatic duct of extrahepatic biliary obstruction. *Radiology*, 1980; 135: 142-145.
9. WalshP.F et al: the value of immediate ultrasound in acute abdominal conditions. A critical appraisal, *Clinical Radiology*, 1990; 42: 47-49.
10. Filly R.A., Freimans A.K: echogenic diagnosos of pancreatic lesion. *Radiol*, 1970; 96: 575.
11. Duncan J.G, Irvine C.W: Ultrasound in management of acute pancreatitis and its complications. *Br J Radiol*, 1976; 49: 858.
12. Abu Zidem F.M., Zayat I, Shaikh M, Mousa: role of ultrasound in blunt abdominal trauma- prospective study. *EUR j Surg*, 1996; 162: 361-365.
13. Goldstein H.M. Green B: Ultrasonic detection of renal tumor extension into IVC. *AM J Roentgenology*, 1978; 130: 1983-5.
14. Ellenbogen P.H, Scheible: sensitivity of grey scale ultrasound in detecting urinary obstruction. *AM J Roentgenol*, 1978; 130: 731-39.