

PNEUMONO ULTRA MICRO SCOPIC SILICO VOLCANO CONIOSIS: A FIBROTIC LUNG DISEASE - AN IN DEPTH REVIEW**Gourab Saha¹, Soma Das², Rashmi Dorai³, T. P. Rao⁴, Mahima⁵, Bandana Singh⁶, Monu Kumar Kashyap⁷, Rajashekar Perusomula⁸ and Vivek Dhir^{*9}**¹Department of Pharmaceutics, College of Pharmaceutical Sciences, Berhampur, Odisha, India.²Department of Pharmaceutical Technology, School of Health and Medical Sciences: Adamas University, Kolkata, West Bengal, India.³Department of Pharmaceutical Chemistry, NIMS Institute of Pharmacy, NIMS University, Jaipur, Rajasthan, India.⁴Department of Pharmaceutics and Biotechnology, KVSRR Siddhartha College of Pharmaceutical Sciences, Siddhartha Nagar, Vijayawada, Andhra Pradesh, India.^{5,7}Department of Pharmacology, Goel Institute of Pharmaceutical Sciences, Uttar Pradesh, India.⁶Department of Pharmaceutics, Goel Institute of Pharmaceutical Sciences, Uttar Pradesh, India.⁸Department of Pharmacology, Cognitive Science Research Initiative Lab, Vishnu Institute of Pharmaceutical Education & Research, Narsapur, Telangana, India.⁹Department of Pharmacy, Punjab Multipurpose Medical Institute Sehna Distt Barnala, Punjab, India.***Corresponding Author: Vivek Dhir**

Department of Pharmacy, Punjab Multipurpose Medical Institute Sehna Distt Barnala, Punjab, India.

Article Received on 20/10/2023

Article Revised on 10/11/2023

Article Accepted on 30/11/2023

ABSTRACT

PNEUMONULTRAMICROSCOPICSILICOVOLCANOCONIOSIS is a 45-letter English term that causes silicosis, a lung illness produced by inhaling very tiny silica dust, which causes discomfort in the lungs. Silicosis is a chronic lung condition caused by inhaling fine silica dust particles. People who engage in industries where they may be exposed to these microscopic silica particles, such as sandblasting, mining, and construction, are at risk developing silicosis. When individuals inhale the dust of silica, they consume microscopic crystalline silica particles. Such silica dust can induce fluid accumulation and damage tissue in the lungs, reducing your capacity to breathe. Silicosis is a chronic disease that cannot be healed. Treatments alleviate symptoms and manage infections that silicosis patients are prone to. People with silicosis may survive for a lifetime or just a couple of months, depending on the kind. In general, silica dust impairs the ability of the lungs to function properly. Each form of silicosis has a distinct effect on the body: In uncomplicated chronic silicosis, silica dust produces edema in the airways and chest lymphatic nodes, causing difficulties breathing. Swelling in the lungs and symptoms appear sooner in accelerated silicosis than in ordinary silicosis. The lungs become extremely irritated and can fill with fluid in acute silicosis, causing serious difficulty of breath and low oxygenation in the blood levels. Anyone suffering from silicosis may have the following complications: Risk of lung infections and TB is increased. Progressive enormous fibrosis—severe scarring and rigidity of the lung, making breathing difficult. Progressive massive fibrosis can develop in either simple or accelerated silicosis, although it is more prevalent in the accelerated variety, which is characterized by difficulty breathing. The aim of this review paper is to emphasize the detail of causes, pathophysiology, diagnostic method, prevention & treatment of silicosis.

KEY-WORDS: Pneumonoultramicroscopicsilicovolcanoconiosis, Fibrotic, Silicosis, Dyspnea, X-ray.**INTRODUCTION**

The word Pneumonoultramicroscopic silicovolcanoconiosis is intended to mean-

Pneumono- Greek word, means lung-related

Ultra- Latin word, means beyond

Micro- Greek word, means small

Scopic- Greek word, means looking

Silico- Latin word, means like sand

Volcano- Latin word, means volcano

Konis- Greek word, means dust

Osis- Greek word, means condition.^[1]

It's an English term that relates to silicosis, which is a lung condition. It is the longest word published in an English dictionary, the Oxford English Dictionary. The Oxford English Dictionary defines it as "an artificially

long word said to mean a lung disease caused by inhaling very fine ash and sand dust."^[2]

Silicosis is a type of occupational lung disease produced by inhaling crystalline silica dust, and it is characterized by swelling as well as scarring in the uppermost regions of the lungs in the form of nodular lesions.^[3] Grinder's disease, Black lung disease, and Potter's rot are all names for silicosis. Silicosis is a kind of pneumoconiosis that typically affects miners and other laborers who are repeatedly exposed to free crystalline silica dust. Worker contact with crystalline silica causes lung injury because silica particles become stuck in tissue, forming fibrotic nodules and scarring. Silicosis is the medical word for this kind of lung fibrosis.

Pneumonoultramicroscopicsilicovolcanoconiosis is a condition that is caused by a particular exposure to tiny silica dust found in volcanoes.^[4] It is a crystalline form of silicon dioxide (SiO₂) that comprises tridymite, quartz, and cristobalite. Quartz, the most common kind, is a fundamental element in various types of rocks, particularly granite, slate, and sandstone.^[5]

The name *silicosis* is classified as

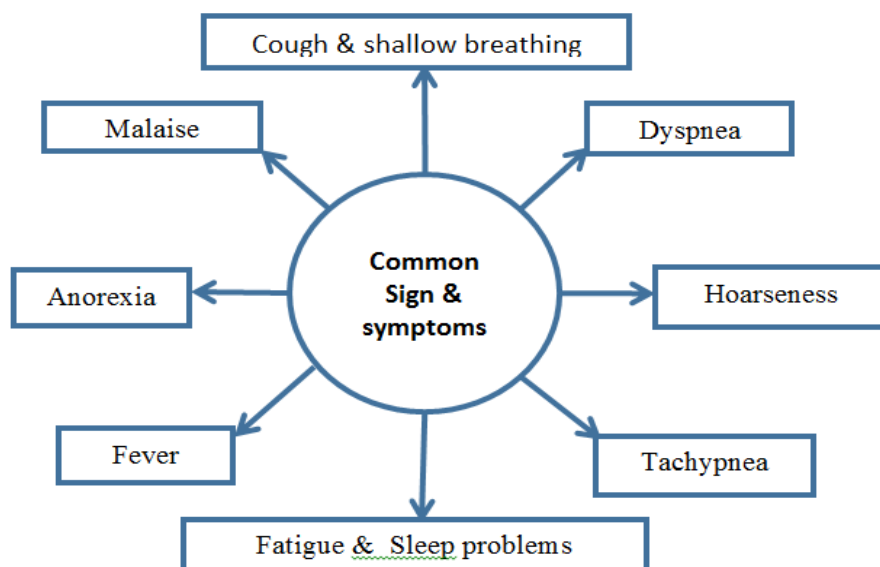
- 1. Chronic simple silicosis:** Typically caused by prolonged consumption (10 years or more) to relatively low quantities of silica dust and manifesting 10-30 years after initial exposure. The most frequent kind of silicosis. Patients with this kind of silicosis may not have visible indications or symptoms of illness, especially early on, although anomalies may be found by x-ray. Chronic cough and severe dyspnea are frequent symptoms. Chronic uncomplicated silicosis is characterized by a profusion of tiny (10 mm diameter) opacities that are generally rounded and predominate in the upper lung zones.^[3]
- 2. Acute silicosis:** Silicosis, which develops between a few weeks over five years after being exposed to

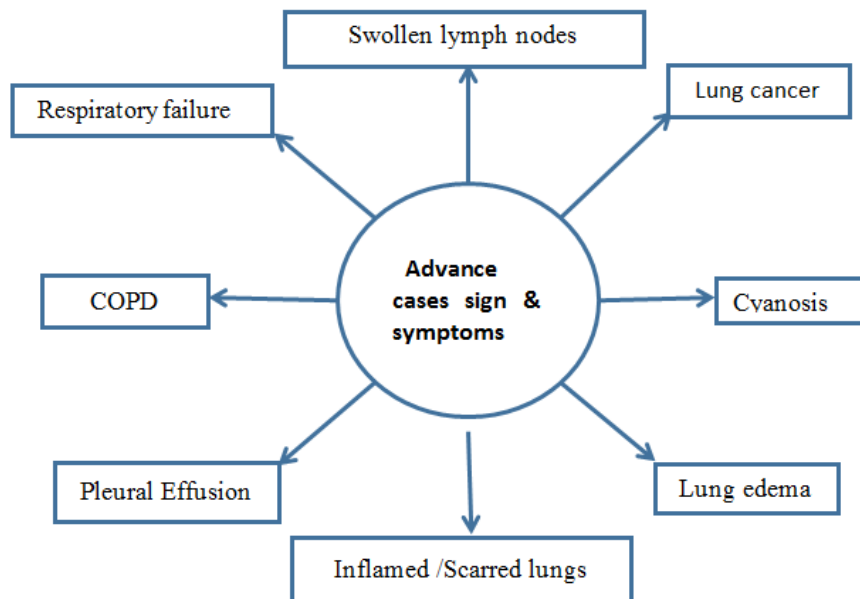
high amounts of inhaled silica dust. This is sometimes referred to as silicoproteinosis. Acute silicosis symptoms include a more faster onset of severe crippling difficulty of breath, cough, weakness, and loss of weight, which can lead to death. The X-ray generally shows a diffuse alveolar filling with air bronchograms, which is comparable to pneumonia, pulmonary edema, alveolar hemorrhage, and alveolar cell carcinoma of the lungs.^[6]

- 3. Complicated silicosis:** Silicosis can be "complex" by the occurrence of serious scarring (progressive massive fibrosis, also known as conglomerate silicosis), in which the microscopic nodules gradually become confluent and grow to be 1 cm or larger in size. In comparison to mild illness, PMF has been associated with more significant symptoms and respiratory impairment. Other lung disorders, including tuberculosis, non-tuberculous mycobacterial infection and fungal infection, certain autoimmune diseases, and lung cancer, can also worsen silicosis. Complicated silicosis occurs more frequently in accelerated silicosis than in chronic silicosis.^[7]
- 4. Accelerated silicosis:** Silicosis occurs 5-10 years after initially being exposed to greater amounts of silica dust. The symptoms and X-ray results are comparable to chronic simple silicosis, except they appear sooner and worsen more quickly. Patients with accelerated silicosis are more likely to develop severe illness, such as progressive massive fibrosis (PMF).^[8]

SIGN AND SYMPTOMS^[9-10]

Pneumonoultramicroscopicsilicovolcanoconiosis is slow to develop; signs and symptoms may not appear until years after exposure. Signs and symptoms include the following





CAUSES

Pneumoconiosis does not appear quickly. It occurs after years of exposure to fine mineral or chemical particles, such as silica, coal dust, or asbestos. When dust particles accumulate in lungs, they get into action. It perceives the dust particles as intruders and attempts to destroy them.

During this phase, lung tissue is frequently irritated. As a result, scar tissue in the lungs may grow, just as it would after an accident. Because scar tissue is less elastic than ordinary lung tissue, taking a complete, deep breath may become more difficult.^[11]

PATHOPHYSIOLOGY^[12,13]

Silica dust becomes fixed in the ducts and tiny alveolar sacs of the lungs after being breathed.



The conversion of O₂ and CO₂ occurs. Ingestion of dust particles, as well as the production of leukotriene B₄, interleukin-1, and other cytokines, might cause an inflammatory response.



Encourage collagen synthesis and fibroblast growth by encircling the silica particle. Fibrosis results in nodular lesions. The NALP3 inflammasome may be involved in the inflammatory activity of crystalline silica.

Microscopic pathology in acute silicosis indicates granular infiltration of the walls of the alveolar and alveolar exudate containing periodic acid schiff positively.

DIAGNOSIS

Following methods can be used for the diagnosis of this disease

1) Occupational history of crystalline silica exposure.

- 2) Standard chest X rays.
- 3) Ruling out other possible diseases.

1. Occupational History

A complete work history of cases must be acquired in order to evaluate cumulative exposure to crystalline silica. This is a challenging job for physicians, especially when the person who is impacted constantly changes occupations. Regardless, historical and present employment actions, in addition to the period of particle contact, have to be recorded.^[14,15]

2. Standard Chest X-ray

On the basis of high-quality chest X-rays, experienced and competent clinicians can diagnose silicosis.^[15]

3. Ruling out other Diseases

Several other differential diagnostic tests are performed by the clinician on a case-by-case basis to rule out other diseases. Some of these additional tests are as follows: -

i. Lung Function Tests: - These tests assess your lung's ability to breathe properly and deliver oxygen to your bloodstream. Two separate tests are used to make these measurements: spirometry and diffusion capacity. They are also used to assess the extent of damage to your lungs.^[16]

ii. High Resolution Computed Tomography (HRCT)

The HRCT technique is helpful in identifying alterations in vascular anatomy and lung architecture, such as calcification of nodules in some lung regions. According to reports, HRCTs are more accurate than X-rays in identifying silicosis. Yet, according to various studies, the approach has more drawbacks than benefits. Standards for reading HRCTs are not sufficiently clear, which raises the possibility of diagnoses being made in circumstances when they are not. A generalised

application of this approach would result in the observation of lung nodules with unknown significance, which would cloud the diagnosing process. Additionally, the employer could consider the employee unfit for the position based on these results. Hence, it is not advised to utilise it in the diagnosis of silicosis.^[15,17]

iii. Progressive Massive Fibrosis

Manifests as bilateral upper lobe masses that are made up of nodules that have coalesced. Cavitation could be noticed. Fibrosis may cause these masses to withdraw towards the hilum, giving the lower lung fields the appearance of being inflated. There could be calcifications in the hilar.^[5]

iv. Histology Findings

One of the most useful diagnostic techniques for identifying silica-induced lung injury is histopathological analysis of the lungs. Comprehensive pulmonary pathology assessment using when a patient is exposed to pure silica, separate nodules that are exceedingly hard and vary in colour (grey, blue, or green) have been seen in simple silicosis; nevertheless, those nodules can also be black (coal miners' silicosis) or red (silicosis in a hematite miner). Aggregates of dust-filled macrophages that are nodular to stellate in shape and gathered around a collagenous core area can be used to identify these early lesions. A decreased relative number of inflammatory cells around the periphery over time causes the central collagen to become clearly whorled. When silica and another dust, such as iron oxide, are combined to cause mixed dust pneumoconioses, the nodules typically retain their stellate structure, although the core collagen region exhibits comparatively less of the spiral pattern that is typically seen in typical silicosis.^[18]

PREVENTION^[9,13]

1. Primary prevention

- To monitor levels of respirable dust
- To recommend personal protection measures
- 2. Secondary prevention
- To monitor exposed workers
- Stopping smoking
- Monitoring for tuberculosis
- Tertiary prevention
- Avoid exposure to dust particles
- Report cases, recommend occupational disease assessment
- To monitor for tuberculosis infection

TREATMENT

Silicosis is an incurable disease with no treatment. Treatment options now focus on symptom relief and avoiding complications. Stopping subsequent exposure to silica along with other lung irritating substances, particularly tobacco smoking, cough suppressive medications, and medications for bacterial lung infection are among them. Prophylaxis against tuberculosis for persons who have a positive tuberculin skin test or an IGRA (Interferon-release assays) blood test. Prolonged

anti-tuberculosis treatment (multi-drug regimen) for those with active tuberculosis. Chest physiotherapy to aid mucus discharge in the bronchi. If hypoxemia is evident, oxygen should be administered. Bronchodilators are used to make breathing easier. Lung transplantation to replace destroyed lung tissue is the most successful therapy, but it comes with its own set of hazards. Broncho-alveolar lavage may relieve symptoms of acute silicosis, but it does not reduce overall mortality. Inhalation of powdered aluminum, dpenicillamine, and polyvinyl pyridine-N-oxide are among the experimental therapies. Corticosteroid treatment. Tetrandine, a plant extract, may decrease the growth of silicosis.^[19,20]

CONCLUSION

Although pneumonoultramicroscopicsilicovolcanoconiosis (silicosis) is unable to be treated, the key to treating the illness is prevention. Silicosis is still a severe occupational health concern for workers in the mining, foundry, and constructions industries. It contributes significantly to lung disease and pulmonary function deterioration. TB is a common comorbidity that aggravates the silicosis condition. Other serious issues including lung cancer and connective tissue abnormalities. Silicosis cannot be treated, but it may be avoided if you take the necessary steps to protect your family and yourself. To lower the worldwide burden of silicosis, it is critical to lessen exposure through a range of prevention interventions and regular examinations for early diagnosis.

CONFLICT OF INTEREST

The authors declare that the review was conducted in the absence of any commercial or financial relationships that could be construed as a potential conflict of interest.

ACKNOWLEDGEMENT

The authors are thankful to their institutes.

FUNDING

None.

REFERENCES

1. Definition of pneumonoultramicroscopicsilicovolcanoconiosis in Oxford dictionary (British and World English). Oxford Dictionaries. Oxford University Press, 2012.
2. Cole Chris Wordplay, A Curious Dictionary of Language Oddities. Sterling Publishing Co., Inc., 1999; 106–107.
3. Pelucchi C, Pira E, Piolatto G, Coggiola M, Carta P, La Vecchia C, et al. Occupational silica exposure and lung cancer risk: a review of epidemiological studies 1996-2005. *Ann. Oncol*, 2006; 17(7): 1039–1050.
4. Dr. PK Nag, SILICA & DISEASES, ENVIS-NIOH, National Institute of Occupational Health, 2009; 4(1).

5. V. Hemavathy & V. J. Binipaul, Silicosis- An Occupational Hazard, TJPRC: International Journal of Nursing and Patient Safety Care, 2016; 1(2). Published on: 19.
6. Sahu AP, Saxena AK, et. al. Enhanced Translocation of Particles from Lungs by Jaggery. *Environmental Health Perspectives*, 1994; 102(S5): 211–214.
7. Wagner GR Asbestosis and silicosis. *Lancet*, 1997; 349(9061): 1311–1315.
8. Cassel SL, Eisenbarth SC, Iyer SS, et al. The Nalp3 inflamed some is essential for the development of silicosis. *Proc. Natl. Acad. Sci. U.S.A.* 2008; 105(26): 9035.
9. Shelar KS, Dhamak KB, “Pneumonoultramicroscopicsilicovolcanoconiosis” © 2023 IJCRT, March 2023; 11(3) ISSN: 2320-2882
10. Denise R Eccles, Advance Nursing Institute: Pneumonoultramicroscopicsilicovolcanoconiosis (Black Lung Disease).
11. What Is Pneumoconiosis? Medically Reviewed by Paul Boyce, MD on January 31, 2022, Written by Elizabeth Svoboda <https://www.webmd.com/lung/what-is-pneumoconiosis>
12. GBD 2013 Mortality and Causes of Death, Collaborators. Global, regional, and national age-sex specific all-cause and cause-specific mortality for 240 causes of death, 1990–2013: a systematic analysis for the Global Burden Of Disease Study 2013". *Lancet*, 2014; 385: 117– 71.
13. Rathinam T, Prema S et.al, Overview of the largest health hazard: pneumoconiosis –detected silicovolcanoconiosis, *Journal of Pharmaceutical Negative Results*, 2023; 14(2). DOI: 10.47750/pnr.2023.14.S02.147
14. Ramon Fernandez Alvarez et.al, Guidelines for the Diagnosis and Monitoring of Silicosis, ARCHIVOS DE BRONCHONEUMOLOGIA, Published by Elsevier Espana, Accepted on, 22 July 2014.
15. Shamim Mohammad et al. Silicosis, A Monumental Occupational Health Crisis In Rajasthan-An Epidemiological Survey, *International Journal of Research Granthaalayah: A knowledge Repository*, 2017; 5(7).
16. <https://www.lung.org/lung-health-diseases/lung-disease-lookup/silicosis/symptoms>
17. [diagnosis#:~:text=There%20is%20no%20specific%20test,the%20likelihood%20of%20silica%20exposure](https://www.lung.org/lung-health-diseases/lung-disease-lookup/silicosis/symptoms)
18. Australia and Internationally: A Review of the Literature, *International Journal of Environmental Research and Public Health*, Published on, 31 July 2021.
19. Sukanta Sen et.al, Silicosis in Current Scenario: A Review of Literature, 2016 Bentham Science Publishers.
20. Norboo T, Angchuk PT, Yahya M, et al. Silicosis in a Himalayan village population: role of environmental dust. *Thorax*, 1991; 46(5): 341–343.
21. Steenland K, Goldsmith DF. Silica exposure and autoimmune diseases. *Am J Ind Med*, 1995; 28: 5.