

**FIBULAR NERVE PALSY SECONDARY TO COMPRESSION BY A PROXIMAL TIBIAL
OSTEOCHONDROMA: A CASE REPORT**

¹*MOUN-GOSS Noudjoutobaye, ²CHIPALO Kabwe, ³MAHAMAT Achair Langaba, ⁴ABID Hatim, ⁵ELIDRISSI Mohammed and ⁶ELMRINI Abdelmajid

¹Resident Physician in Orthopaedic and Traumatologic Surgery, Orthopédic and Trauma Department 2, CHU HASSAN II, Fès, Maroc. ORCID Number: 000-0002-3959-2707

^{2,3}Resident Physician in Orthopaedic and Traumatologic Surgery.

^{4,5}Professor in the Departement Orthopaedic and Trauma Surgery 2.

⁶Professor and Head of Orthopaedic and Trauma Surgery 2.



*Corresponding Author: Dr. MOUN-GOSS Noudjoutobaye

Resident Physician in Orthopaedic and Traumatologic Surgery, Orthopédic and Trauma Department 2, CHU HASSAN II, Fès, Maroc. ORCID Number: 000-0002-3959-2707

Article Received on 28/01/2025

Article Revised on 18/02/2025

Article Published on 11/03/2025

ABSTRACT

Introduction: Our study reports a rare case of common fibular nerve palsy caused by compression of an osteochondroma of the proximal tibia, highlighting the need for different diagnostic means and the importance of early management. **Methods:** A 25-year-old man presented with progressive left leg dysfunction, including foot dorsiflexion deficit and step gait. Radiographs and MRI revealed a proximal tibial osteochondroma compressing the fibular nerve. Surgical management included tumour resection, neurolysis and nerve repair. Postoperative management included immobilisation and 12 months of physiotherapy. **Results:** Preoperative evaluation revealed severe neurological deficits and muscle atrophy. Imaging confirmed the compressive nature of the osteochondroma. Surgical decompression and nerve reconstruction were successful and histopathology confirmed the benign diagnosis. Postoperative rehabilitation resulted in partial recovery, with motor strength graded 3/5 at 12 months. Prolonged preoperative compression limited full recovery. **Conclusions:** Fibular nerve palsy due to osteochondroma is rare. Early diagnosis, imaging and surgical intervention combined with structured rehabilitation are crucial to optimise recovery and minimise long-term deficits.

KEYWORDS: Osteochondroma, Common fibula nerve, Compression, nerve palsy.

INTRODUCTION

Benign bone tumors are relatively common and can affect different parts of the human skeleton. Among these tumors, osteochondromas are the most common, accounting for around 20-50% of all benign bone tumors.^[1] They generally occur in young people, with peak incidence observed during the period of bone growth, often between the ages of 10 and 30^[2], and develop mainly from the articular surfaces of long bones, particularly in the metaphyses of tubular long bones, such as the femur and tibia.^[3] Although most osteochondromas are asymptomatic, some can lead to complications such as compression of surrounding structures. In this article, we report a rare case of fibular nerve palsy due to compression by an osteochondroma of the proximal end of the tibia in a 25-year-old man.

PATIENT AND OBSERVATION

A 25-year-old man with no previous history presented to hospital with pain and an inability to bear weight on his left leg. He reported intermittent pain in his left knee, as

well as a tingling sensation when walking, which had developed progressively over the previous five months and led to a total deficit in dorsiflexion of the foot and elevation of the big toe.

Physical examination revealed moderate muscle atrophy, as well as a total deficit in dorsiflexion of the foot leading to stepping on walking and a deficit in extension of the toes on the left side. Osteotendinous reflexes were absent on the affected side, with a positive Hoffmann-Tinel sign.

Standard radiographs of the left knee revealed a well-defined, pedunculated bony growth on the posterolateral aspect of the proximal end of the tibia. MRI was performed to assess the tumour and possible complications. MRI revealed an osteochondromatous exostosis of the proximal left tibia, posterolateral, with poly-lobed contours, associated with a fibular neoarticulation, measuring 57 mm in long axis by 22 x 40 mm in axis, and responsible for compression of the

external popliteal sciatic nerve (SEP). The anterior tibial vascular pedicle was free.

The patient was operated on. The patient was placed in the supine position, with a tourniquet at the base of the thigh. A posterior knee incision was made. An italic 'S'-shaped skin and subcutaneous incision was made from medial to lateral. The fascia was incised and the superficial and deep musculo-nervous elements dissected. An arthrotomy was performed to expose the posterior aspect of the tibia and fibular head. There was total transection of the common peroneal nerve, with frayed and poorly vascularised ends. In addition, there was fibro-inflammatory tissue around the nerve and a bony outgrowth located on the posterolateral aspect of the proximal tibia. Excision of the bony mass, neurolysis and regularisation of the extremities were performed. We then performed an end-to-end perineural suture using Prolene 6/0.

Histopathological examination of the tumor confirmed the diagnosis of benign osteochondroma.

Following surgery, the patient was immobilized for 3 weeks and then underwent intensive physiotherapy to restore muscle function in the affected leg. Long-term follow-up over 12 months showed partial recovery of neurological deficits, with motor strength rated at 3/5.

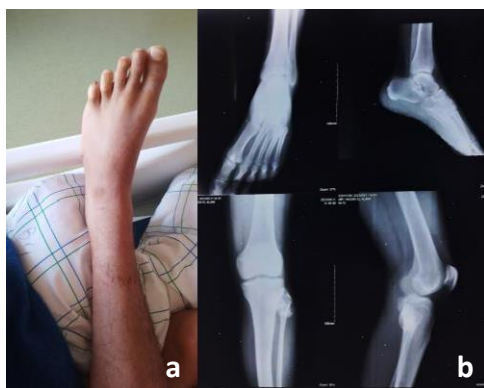

Figure 1: (a) Foot dorsiflexion deficit and (b) radiographic image of proximal tibial exostosis.

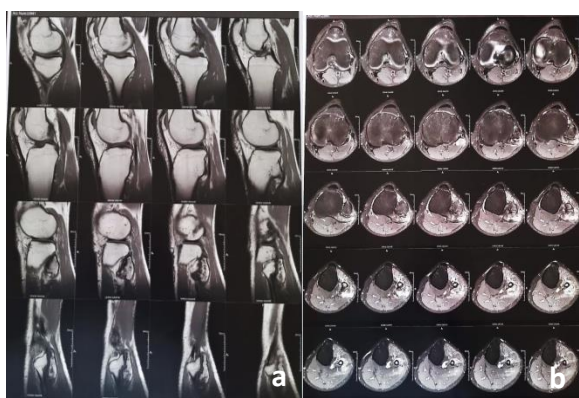


Figure 2: (a, b) MRI sections showing compressive exostosis of the posterolateral aspect of the proximal tibia.

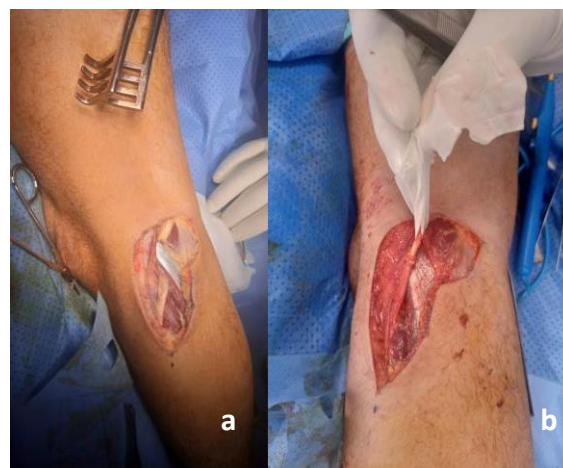

Figure 3: (a,b) Complete rupture of the common fibular nerve; terminoterminal suture of the common fibular nerve.

By the surgical procedure itself. Indeed, the fragility of the compression zone may make the nerve more susceptible to injury during surgical manipulation.

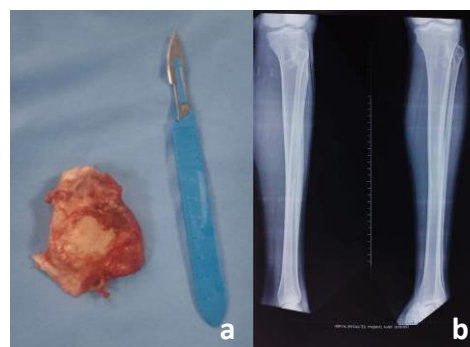


Figure 4: (a, b) Exostosis surgical specimen and post-operative radiograph of the left leg.

DISCUSSION

Osteochondromas are the most common benign bone tumors. However, their compression of surrounding nerve structures remains rare. In particular, compression of the fibular nerve by an osteochondroma located at the proximal end of the tibia is an even more exceptional phenomenon. This compression can lead to a variety of symptoms, including pain, muscle weakness, atrophy and sensory disturbances in the affected limb.^[4] Indeed, a deficit in big toe raising, a steppage gait and a positive Hoffmann- Tinel sign should prompt a search for an EPS nerve lesion. The most frequent area of compression of the EPS nerve is at the point where it bypasses the neck of the fibula.^[5]

Diagnosis of fibular nerve compression by an osteochondroma is based on rigorous clinical evaluation, combined with imaging studies such as X-rays and MRI, which allow visualization of the tumor and its impact on neighboring nerve structures. Definitive diagnosis is often confirmed by histopathological analysis after surgical resection of the tumor.^[6,7,8]

A pertinent question to be raised in this context is whether fibular nerve rupture could be caused not only by the compression exerted by the tumor, but also The treatment of choice in this case remains surgical resection of the osteochondroma, to relieve nerve compression and improve associated symptoms.^[9] Delayed treatment can have irreversible neurological consequences.^[10,11] Post-operative rehabilitation also plays a crucial role in restoring muscle function and mobility, helping to limit long-term sequelae and promote nerve recovery.

Factors influencing prognosis include

- *Duration of nerve compression:* The longer the compression, the poorer the prognosis due to irreversible axon damage.
- *Surgical techniques:* Precise suturing and complete release of compression increase the chances of functional recovery.
- *Post-operative rehabilitation:* Intensive rehabilitation is essential to maximize functional recovery and reduce long-term sequelae.

CONCLUSION

Fibular nerve rupture due to compression of an osteochondroma of the proximal end of the tibia is a rare condition. This case highlights the importance of thorough clinical evaluation and accurate imaging for diagnosis. Surgical resection of the tumor with appropriate rehabilitation can lead to satisfactory functional recovery. Early and appropriate management of these cases is essential to minimize long-term complications and improve patients' quality of life.

CONFLICTS OF INTEREST

There are no conflicting relationships or activities.

FINANCIAL SUPPORT AND SPONSORSHIP

This study did not receive any specific grant from funding agencies in the public, commercial, or not-for-profit sectors.

BIBLIOGRAPHY

1. Murphey MD, Choi JJ, Kransdorf MJ, Flemming DJ, Gannon FH. Imaging of osteochondroma: variants and complications with radiologic-pathologic correlation. *Radiographics*, 2000; 20(5): 1407-1434, DOI:10.1148/radiographics.20.5.g00se041407
2. Kitsoulis P, Galani V, Stefanaki K, et al. Osteochondromas: review of the clinical, radiological and pathological features. *In Vivo.*, 2008; 22(5): 633- 646.
3. Spranger J, Winterpacht A, Zabel B. The type II collagenopathies: a spectrum of chondrodysplasias. *Eur J Pediatr*, 1994; 153(2): 56-65.
4. Cardella JM, Dormans JP, Drummond DS. Proximal fibular osteochondroma with associated peroneal nerve palsy: a review of six cases. *J Pediatr Orthop*, 1995; 15: 574-7.
5. Flores LP, Koerbel A, Tatagiba M. Peroneal nerve compression resulting from Wbular head osteophyte-like lesions. *Surg Neurol*, 2005; 64: 249-252. Discussion 52
6. León-Andrino A, Noriega DC, Lapuente JP, Pérez-Valdecantos D, Caballero-García A, Herrero AJ, et al. Biological Approach in the Treatment of External Popliteal Sciatic Nerve (Epsn) Neurological Injury: Review. *JCM.*, May 16, 2022; 11(10): 2804.
7. De Souza AMG, Bispo Júnior RZ. Osteocondroma: ignorar ou investigar? *Revista Brasileira de Ortopedia*, Nov. 2014; 49(6): 555-64. 1.
8. Drăghici NC, Văcăraș V, Bolchis R, Bashimov A, Domnița DM, Iluț S, et al. Diagnostic Approach to Lower Limb Entrapment Neuropathies: A Narrative Literature Review. *Diagnostics*, Nov. 4, 2023; 13(21): 3385.
9. Flores LP, Koerbel A, Tatagiba M. Peroneal nerve compression resulting from fibular head osteophyte-like lesions. *Surgical Neurology*. Sept. 2005; 64(3): 249-52.
10. Selçuk Göçmen 1, Ali Kıvanç Topuz, Cem Atabey, Hakan Şimşek, Kenan Keklikçi, Osman Rodop, Peripheral nerve injuries due to osteochondromas: analysis of 20 cases and review of the literature, PMID: 24405073. DOI: 10.3171/2013.11.JNS13310
11. Çınar A, Yumrukçal F, Saldız A, Dirik Y, Eralp L. A rare cause of 'drop foot' in the pediatric age group: Proximal fibular osteochondroma a report of 5 cases. *International Journal of Surgery Case Reports*, 2014; 5(12): 1068-71.