

**ANTITHROMBIN III DEFICIENCY: A RARE CAUSE OF ACUTE CORONARY SYNDROME IN YOUNG SUBJECTS**

Dania Srifi\*, Pr Nadia Fellat and Pr Roukaya Fellat

Faculty of Medecine of Rabat, Avenue Mohamed Belarbi El Alaoui B.P.6203 10000, Rabat, Morroco.

**\*Corresponding Author: Dania Srifi**

Faculty of Medecine of Rabat, Avenue Mohamed Belarbi El Alaoui B.P.6203 10000, Rabat, Morroco.

Article Received on 12/08/2021

Article Revised on 02/09/2021

Article Accepted on 23/09/2021

**ABSTRACT**

Acute coronary syndrome due to antithrombin III deficiency has been rarely reported. We report case of a 42-year-old patient, with a sudden death mother at the age of 30, who presenting myocardial infarction, complicated of VG dysfunction with angiography of healthy coronary arteries. 9 months later the patient had a pulmonary embolism. the etiological diagnosis made has retained in front of this recurrence of thrombosis a deficiency of antithrombin III.

**KEYWORDS:** Acute coronary syndrome Young adult Antithrombin III deficiency.**INTRODUCTION**

Antithrombin (AT) belongs to the family of serine protease inhibitors. Its constitutional deficit is highly thrombogenic, especially on the venous level, more rarely arterial. A young patient with multiple thromboembolic events related to AT III deficiency is reported.

**CASE REPORT**

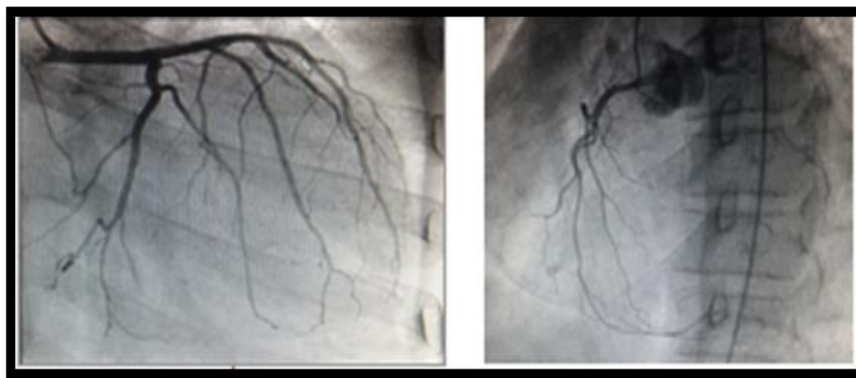
This is a 42-year-old patient from a first-degree consanguineous marriage, with a sudden death mother at the age of 30, who presented in a picture of prolonged chest pain associated with transient left hemiparesis. The clinical examination finds a patient who is hemodynamically stable with a normal cardiovascular examination.

The ECG finds a sub-offset of the ST segment in ASA. The biological balance is normal apart from a troponin at 27 and elevated cardiac enzymes ETT shows global VG hypokinesis with an ejection fraction at 45%. Coronary angiography is performed returning normal. Faced with the diagnosis of SCA with healthy coronaries, an etiological assessment was requested but not done by the patient. She was released on aspirin, beta-blocker and IEC.

She presents 9 months later in a picture of acute dyspnea with hemoptoic sputum. The clinical examination this time finds a tachycardia patient at 110 bpm with cardiovascular examination edema of the lower limbs. The ECG shows sinus tachycardia with an incomplete right branch block appearance. ETT reveals slightly dilated straight cavities with moderate HTAP.

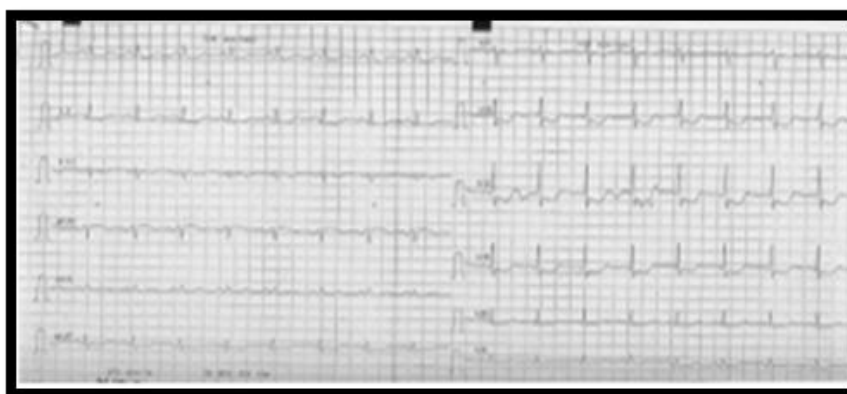

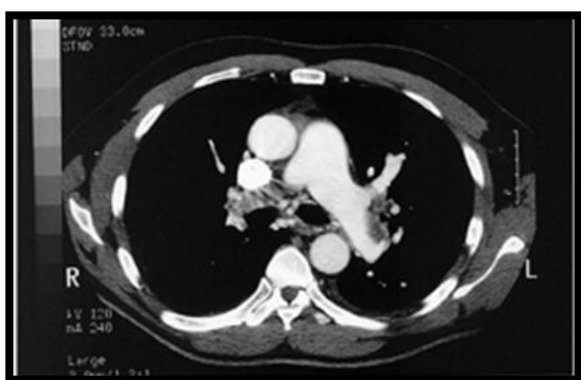Figure 1: ECG.



**Figure 2: Coronary angiography.**

The diagnosis of a pulmonary embolism was suspected and confirmed on the thoracic angioscanner which shows an absence of opacification of the right lower lobar branch.

An etiological assessment carried out finds a deficiency in antithrombin III (an activity at 19%). The patient was put on Sintrom. The control ETT, one year later, shows dilated biventricular cardiomyopathy in severe VG dysfunction.



**Figure 3: The thoracic angioscan.**

## DISCUSSION

AT III is a progressive inhibitor of thrombin and most serine-proteases of the coagulation, the activity of which is considerably accelerated by the heparin. Synthesized in the liver, this glycoprotein has the largest part of its activity in plasma antithrombotic.

The determination can be carried out by methods functional that test a biological activity (tests of coagulation or chromogenic techniques) or by immunological methods that recognize protein.

There is a decrease in the physiological activity of AT III in the newborn, the elderly, the woman in the period of genital activity, at the end of pregnancy, and in the immediate postpartum.

The AT III is lowered in many pathological or therapeutic situations, in particular, nephrotic syndrome,

coagulopathy of consumption, hepatic cirrhosis, diabetes, treatments with heparin, estrogens or asparaginase.

If the acquired deficits are the most frequently met, the impact of the constitutional deficit in AT III should not be underestimated; according to the Scandinavian authors, this genetic anomaly would affect 1/2,000 to 1/5,000 people; it would be responsible for at least 2 per cent of thromboembolic accidents.<sup>[1,2]</sup>

Antithrombin III deficiency is usually associated with venous thrombosis; arterial thrombosis is rare.

Acute coronary syndrome in young adults is an uncommon condition; only 2–8% of acute myocardial infarction subjects are under 40 years' old. Males are typically more affected, females account for only 6% in this age group.<sup>[3]</sup> It may have non-atherosclerotic etiologies, as is the case of our patient.

Limited studies have focused on the management of acute coronary syndrome in the young, but percutaneous coronary intervention gives good results. In hypercoagulable states, long-term anticoagulation should be considered.<sup>[5]</sup>

It is therefore necessary to dose systematically AT III in any subject presenting a personal or family history of recurrent phlebitis, deep vein thrombosis, infarction venous visceral or unusual resistance to heparin treatment. The hereditary character is proved by the family survey. Heparinotherapy only allows the rapid treatment of recent thromboembolic accidents; oral anticoagulants in the long run will be used for prophylactic purposes.<sup>[6,7]</sup>

## REFERENCE

1. BENNET B., MACKIE M., DOUGLAS A. S.: Familial thrombosis due to antithrombin III deficiency; an extensive family study, *Thromb. Haemostas*, 1977; 38: 78.
2. BESSOT J.-C., QUOLX E., CHARBONNEAU J., BURGHARD G., WIESEL M. L., KALOGJERA N., MAYER S., MAYER G.: Déficit héréditaire en antithrombine III responsable d'accidents

- thromboemboliques recidivants. *Nouv. Presse Med.*, 1978; 7: 999-1002.
3. Teixeira M, Santos Mendes I, Martins L. Acute coronary syndrome in young adults. *Rev Port Cardiol*, 2010; 29: 947–55.
  4. Aguiar C. Acute coronary syndrome in younger patients: an avoidable atherothrombotic complication. *Rev Port Cardiol*, 2010; 29: 957–60.
  5. Osula S, Bell GM, Hornung RS. Acute myocardial infarction in young adults: causes and management. *Postgrad Med.*, 2002; 78: 27–30.
  6. PETERS T., LEwis J., FILIP D., MORRIS L.: Antithrombin III deficiency causing post splenectomy mesenteric venous thrombosis coincident with thrombocytopenia. *Ann. Surg.*, 1977; 185: 229-231.
  7. WATEL A., GOUDEMANT J., ZANDECKI M., LAISNE C., BERTRAND M.-E., COSSON A.: Deficit familial en antithrombine III et maladie thromboembolique. *Lille Med.*, 1978; 23: 555-560.